

1. ANATOMY

1. INTRODUCTION

Anatomy is a science that deals with the structures of the body and the relationship of various parts to each other. A knowledge of these structures is necessary to understand their functions.

The subject matter of Anatomy includes:

- | | | | |
|----|---------------|---|-----------------------------|
| 1. | Cytology | - | study of cells |
| 2. | Histology | - | study of tissues |
| 3. | Osteology | - | study of bones |
| 4. | Myology | - | study of muscles |
| 5. | Arthrology | - | study of joints |
| 6. | Splanchnology | - | study of organs |
| 7. | Neurology | - | study of the nervous system |

Descriptive terms used in Anatomy :

The arrangement of various parts of the body may be:

- i) Symmetric e.g. limbs, eyes, ears and lungs. Their arrangement on the right side and left side are similar.
- ii) Asymmetric e.g. spleen and liver. The spleen lies entirely in the left side. Liver lies mostly on the right side.

The study of human body is done in *anatomical position*. In this position, the body is erect, the head facing forwards, arms by the sides and palms of hand facing forward.

1. **Median line** (mid saggittal plane): The central plane which divides the 'body into two halves i.e. right and left.

- | | | | |
|----|-----------|---|---|
| 2. | Medial | : | Nearer to the median line |
| 3. | Lateral | : | Away from the median line |
| 4. | Superior | : | Nearer to the head |
| 5. | Inferior | : | Nearer to the foot |
| 6. | Anterior | : | Nearer to the front surface of the body |
| 7. | Posterior | : | Nearer to the back surface of the body |
| 8. | Proximal | : | Nearer to the origin of the structure |
| 9. | Distal | : | Away from the origin of the structure |

10. Superficial : Nearer to the skin surface
11. Deep : Deeper from the skin surface

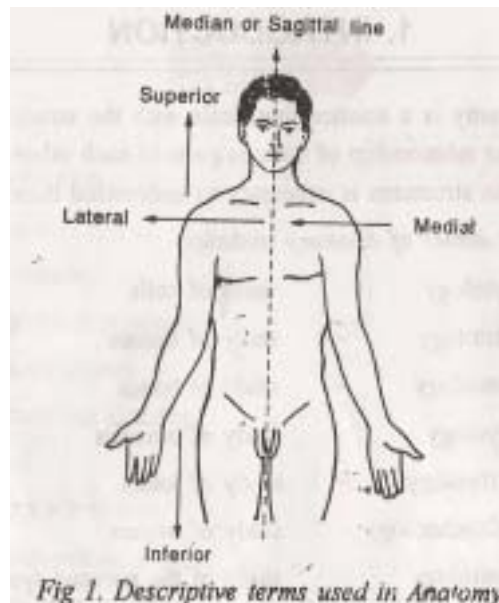


Fig 1. Descriptive terms used in Anatomy

Physiology is the science of life which deals with normal functions of the body. It explains how various systems in the body function together normally as a single unit.

The subject matter of Physiology includes the study of various systems like:

1. Central nervous system
2. Cardiovascular system
3. Digestive system
4. Excretory system
5. Respiratory system
6. Reproductive system etc.

B. SYSTEMS OF THE BODY

ORGANS OF THE BODY

An organ is a group of tissues arranged in a certain way to carry out a specific function e.g. stomach, heart, kidneys. The human body is a highly developed multicellular organism containing various organs which perform different functions. The organs are again grouped together to form systems.

SYSTEMS OF THE BODY

A system is a group of organs which together carry out one of the essential functions of the body. The following are some important systems.

1. Skeletal system:

It is formed by bones. It provides a frame work for the body. Also, it protects the soft tissues and allows movements at joints.

2. Muscular system:

It is made of numerous muscles. It effects movements of the body as a whole.

3. Circulatory system:

It includes heart, blood vessels and blood. This system carries oxygen and nutrients to various tissues of the body.

4. Respiratory system:

It consists of air passages and the lungs. It allows exchange of gases between the body and the environment.

5. Digestive system:

It consists if alimentary canal. It is concerned with digestion and absorption of food and elimination of waste materials.

6. Endocrine system:

It consists of ductless glands. It is concerned with the production of hormones which regulate a variety of function of the body.

7. Urinary system:

It is formed by kidneys, ureter, urinary bladder and urethra. It is concerned with the elimination of waste products of the body.

8. Nervous system :

It consists of brain, spinal cord and nerves. This system creates awareness of the environment such that the body can respond by adapting.

9. Reproductive system:

It consists of genital organs which are different in males and females. This system is responsible for the survival of the species by reproduction.

C. CELL

The cell is the smallest unit of living tissues. Cells of different tissues perform different functions. A cell is made up of the following structures:

1. Cell wall :

It is the external boundary of the living cell. It is a three layered structure made up of lipids and proteins. It measures approximately 70 Å in thickness. The cell wall allows the diffusion of substances into and out of the cell.

2. Nucleus:

It is the largest structure present almost in the centre of a cell. It is more or less spherical in shape. It is bounded by nuclear membrane. The nucleus contains:

- a) nucleolus
- b) chromatin

a) Nucleolus:

It is a highly coiled filamentous structure present in the nucleus. It is not surrounded by a membrane. But it contains numerous granules. Nucleolus is the site of ribosomal RNA (ribonucleic acid) synthesis.

b) Chromatin:

These are fibrous threads present in the nucleus. They are composed of DNA (deoxy ribonucleic acid) and proteins. The chromatin threads carry genetic information. At the time of cell division, chromatin condenses into chromosomes. The number of chromosomes is constant for a particular species of organism. In man, there are 23 pairs of 46 chromosomes.

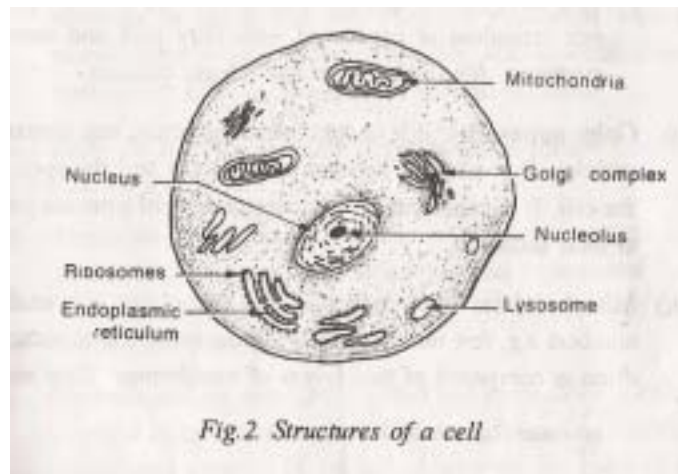
3. Cytoplasm:

It is the region lying between the cell membrane and nucleus. The cytoplasm contains cell organelles like endoplasmic reticulum, golgi apparatus, mitochondria, lysosomes and centrosome.

Microsomes :

They are extremely small bodies present in the cytoplasm. They can be separated by centrifuging a tissue homogenate at very high speed (10000 rpm). Microsomes contain 1) Ribosomes 2) Granular matrix. Ribosomes are concerned with protein synthesis. Granular matrix contains:

- i) "Oxidases" which generate hydrogen peroxide.
- ii) "Catalase" which converts hydrogen peroxide into water.



Organelles of cytoplasm : Following are the important organelles present in the cytoplasm:

i) Endoplasmic reticulum :

It is the most extensive cell organelle present in cytoplasm. It consists of two membranes which are separated by a space.

Endoplasmic reticulum is of two types. They are

a) Granular or rough surfaced endoplasmic reticulum containing ribosomes. The ribosomes are the sites of protein synthesis.

b) Agranular or smooth surfaced endoplasmic reticulum.

This does not contain ribosomes. This type of endoplasmic reticulum is concerned with fatty acid and steroid synthesis. Also, they store and release calcium.

ii) Golgi apparatus :

It is a cup shaped structure and contains vesicles. It is situated between the nucleus and the apex of the cell. It is concerned with concentration of proteins prior to their secretion.

iii) Mitochondria :

They occur in the cytoplasm at variable numbers e.g. few hundreds to few thousands. The mitochondrion is composed of two layers of membranes. They are:

1. an outer layer which is smooth.
2. an inner layer folded into sheets of tubules called *cristae*.

Both these layers enclose a central cavity called *matrix*.

The mitochondria are made up of proteins, phospholipids and some ribonucleic acid. They also contain some important enzyme systems. The mitochondria are chiefly concerned with cellular oxidation.

iv) Lysosomes:

They are small spherical or oval bodies surrounded by a single membrane. They vary in number and contain a variety of hydrolytic enzymes. The lysosomes breakdown bacteria and cell debris engulfed by the cell. The damaged intracellular organelles are also broken down and digested by lysosomes.

v) Centrosome :

It is a small rod shaped body found near the nucleus. It plays an important role during cell division. The centrosome is surrounded by a radiating thread like structure. It contains two centrioles.

vi) Microtubules:

They are straight, hollow cylinders with a diameter of about 200 Å. They are concerned with the maintenance of cell shape. They are also associated with movements of cilia, flagella and mitotic spindles.

Functions of a cell: The following are the important functions performed by a cell.

1. Ingestion and assimilation :

The cell ingests chemical substances like amino-acids from intercellular or interstitial fluid. These substances are used to build up complicated substances like proteins.

2. Growth and repair :

The ingested and assimilated materials are used to synthesise new protoplasm. This leads to increase in size and growth of the cell. Also worn out parts of the cell are replaced by this process.

3. Metabolism: This involves two processes:

- i) *Anabolism* in which the ingested and assimilated food material is used for growth and repair.
- ii) *Catabolism* in which food material is broken down to

release energy for various functions of the cell.

4. **Respiration :**

It involves transport of oxygen from lungs through blood to the tissues and removal of waste products like carbon dioxide. This is essential for the survival and functions of a cell.

5. **Excretion:**

The cell eliminates waste products resulting from catabolism into the interstitial fluid. These products are carried by blood for elimination through lungs and kidneys.

6. **Irritability and contractility:**

The cell is active by means of these two functions. The cell responds to any stimulus (like physical, chemical, thermal, electrical and mechanical) by contracting. Or the impulse is conducted as that occurs in a nerve cell.

7. **Reproduction:**

After growing to an optimum size, the cell divides into daughter cells. Reproduction of cells occurs by mitosis or meiosis.

MITOSIS:

This occurs in four stages namely 'prophase', 'meta phase,' 'anaphase' and 'telophase'.

1. **Prophase:**

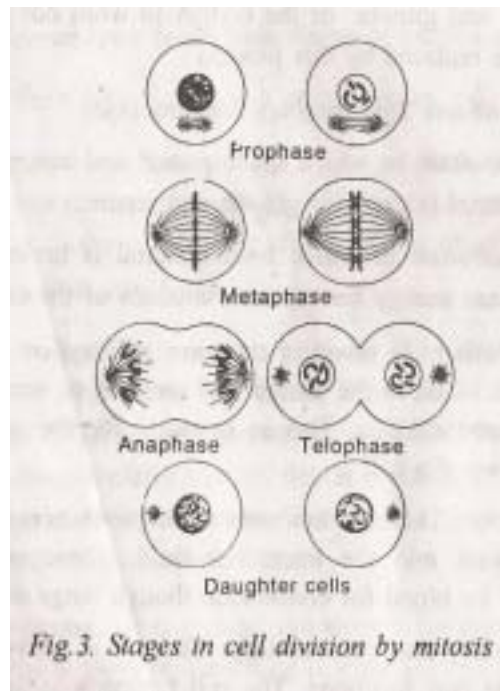
Initially, the centrosome divides into two. These two new centrosomes move away from each other to the two ends of the nucleus forming two poles.

2. **Metaphase:**

Now, the nuclear membrane disappears. The chromosomes arrange themselves around the centre of the cell. They get attached to thread like structures of the centrosomes which are now at the two poles of the cell.

3. **Irregular bones:**

They do not fall in any category e.g. vertebrae and bones of the face.



5. Sesamoid bones:

These are small bones which develop in the tendons of muscles e.g. patella of knee Joint.

3. Anaphase:

The chromosomes now divide longitudinally into two equal parts. The two groups of chromosomes move away to the poles and get arranged around the centrosomes.

4. Telophase:

The cell becomes narrower at the centre to facilitate division. The thread like structures disappear. The nuclear membrane appears again. At the end of telophase, the cell divides. Also, the chromosomes disappear into the nucleus. The daughter cells grow and in turn reproduce by mitosis. During mitosis, each chromosome duplicates. So, the daughter cell contains forty six chromosomes.

MEIOSIS:

It is a process of reproduction which occurs in higher animals including man. It involves the fusion of:

1)'Spermatozoon' from the male (which contains 23 chromosomes and ii) 'Ovum' from the female (which also contains 23 Chromosomes. The spermatozoon and ovum are also called as 'gametes'. The fusion of these two (male and female) gametes results

in the formation of a zygote which has the normal number of 46 chromosomes (23 pairs). This leads to mixing of the hereditary determinants or genes from the male and female.

Determination of sex: One pair of chromosomes from the father and one pair from the mother are sex chromosomes. These sex chromosomes determine the sex of the child. In the female, the sex chromosomes are the same and are called XX. In the male, they are different and are called XY. One chromosome from each pair determines the sex of the child.

If the child has X chromosomes from the mother and X chromosome from the father, it is a female (XX). If the child has X chromosome from the mother and Y chromosome from the father it is a male (XY).

2.OSTEOLOGY

TERMS USED FOR DESCRIBING THE POSITION OF THE BODY

a.Anatomical Position

In this position, the body is erect, the eyes look straight to the front, the upper limbs hang by the side of the trunk with the palms directed forwards, and the lower limb are parallel with the toes pointing forwards.

All structures are described presuming the body in anatomical position, although during study the body may be placed in any position.

b.Supine Position :

Lying down (Recumbent) position with the face directed upwards

c.Prone position :

Lying down (Recumbent) position with the face directed downwards.

d.Lithotomy position

Lying supine with the buttocks at the edge of the table, the hips and knees fully flexed, and the feet strapped in position.

Terms of Relation Commonly used in Gross Anatomy

- | | | | |
|----|-----------|---|----------------------------|
| a. | Anterior | - | Towards the front |
| b. | Posterior | - | Towards the back |
| c. | Superior | - | Towards the head |
| d. | Inferior | - | Towards the feet |
| e. | Medial | - | Towards the median plane |
| f. | Lateral | - | Away from the median plane |

Terms of Relation Commonly used in Embryology and Comparative Anatomy, but sometimes in Gross Anatomy

- | | | | |
|----|--------------------|---|-----------------------------------|
| a. | Ventral | - | Towards the belly (like anterior) |
| b. | Dorsal | - | Towards the back (like posterior) |
| c. | Cranial or Rostral | - | Towards the head (like superior) |

- d.Caudal - Towards the tail

Special Terms for Limbs

- a.Proximal - Nearer to the trunk
- b.Distal - Away from the trunk
- c.Radial - The outer border in the upper limb
- d.Ulnar - The inner border in the upper limb
- e.Tibial - The inner border in the lower limb
- f.Fibular - The outer border in the lower limb
- g.Preaxial border - The outer border in the upper limb, and the inner border in the lower limb.
- h.Postaxial border - The inner border in the upper limb, and the outer border in the lower limb.
- i.Flexor surface - The anterior surface in the upper limb, and the posterior surface in the lower limb.
- j.Extensor surface - The posterior surface in the upper limb, and the anterior surface in the lower limb.
- h.Palmar or Volar - Pertaining to (towards) the palm of the hand.
- l.Plantar - Pertaining to (towards) the sole of the foot

Certain Other Terms

A.Terms used for hollow organs

- a.Interior or inner
- b.Exterior or outer
- c.Invagination or inward protrusion, and
- d.Evagination or outward protrusion

B.Terms used for solid organs

- a.Superficial, towards the surface, and
- b.Deep, inner to the surface

C.Terms used to indicate the side

- a. Ipsilateral -of the same side, and
- b. Contralateral - of the opposite side

Terms used for Describing Muscles

- a. Origin The end of a muscle which is relatively fixed during its contraction.
- b. Insertion The end of a muscle which moves during its contraction.
The two terms, origin and insertion, are sometimes interchangeable, when the origin moves and the insertion is fixed.
- c. Belly The fleshy and contractile part of a muscle
- d. Tendon The fibrous, noncontractile and cord-like part of a muscle.
- e. Aponeurosis The flattened tendon.
- f. Raphe The fibrous band made up of Interdigitating fibres of the tendons or aponeuroses. Unlike a ligament, it is stretchable. Ligaments are fibrous, inelastic bands which connect two segments of a joint.

TERMS USED FOR DESCRIBING MOVEMENTS

- a. Flexion
Approximation of the flexor surfaces whereby the angle of the joint is reduced.
- b. Extension
Approximation of the extensor surfaces whereby the angle of the joint is increased. It is opposite to flexion
- c. Adduction
Movement towards the central axis
- d. Abduction
Movement away from the central axis. It is opposite to adduction
- e. Medial rotation
Inward rotation
- f. Lateral rotation
Outward rotation
- g. Circumduction
Various combinations of the foregoing movements (a to d)
- h. Pronation
Rotation of the forearm so that the palm is turned backwards

OSTEOLOGY

13

- i. Supination
Rotation of the forearm so that the palm is turned forwards
- j. Protraction
Forwards protrusion
- k. Retraction
Movement reverse of protraction

Terms used for Describing Vessels

a."Arteries" carry oxygenated blood away from the heart, with the exception of the pulmonary and umbilical arteries which carry deoxygenated blood. Arteries resemble trees because they have branches (arterioles)

b."Veins" carry deoxygenated blood towards the heart, with the exception of the pulmonary and umbilical veins which carry oxygenated blood veins resemble rivers because they have tributaries (venules)

c."Capillaries" are networks of microscopic vessels connecting arterioles to venules

d."Anastomosis" is a precapillary or postcapillary communication between the neighbouring vessels.

SKELETAL SYSTEM

SKELETAL SYSTEM :

Bones and joints form the skeletal system of the body. Functions of the skeletal system are:

1. Support and protection of soft tissues and vital organs.
2. To give attachment to muscles.
3. Formation of red blood corpuscles in the bone marrow.
4. Storage of mineral salts like phosphorus and calcium.

CLASSIFICATION OF BONES: Bones of the skeleton are classified as:

1.Long bones:

They are found in the limbs. A long bone contains a shaft

and two extremities. The long bones act as levers and help in various movements of the body.

2. Short bones:

These have no shaft. But they contain a spongy substance covered by a shell of compact bone e.g. small bones of wrist and ankle.

3. Flat bones:

They contain two layers of compact bone with a spongy substance in between e.g. pelvic bones and scapula.

These are small bones which develop in the tendons of muscles e.g. patella of knee Joint.

STRUCTURE OF BONE:

Bone is the hardest of the connective tissues. It consists of two kinds of connective tissues 1) Compact bone 2) Cancellous bone.

Compact bone:

It is hard and dense. It is found in flat bones, in the shafts of long bones and as a thin covering of all bones.

Cancellous bone :

It is spongy in appearance. It is found in the ends of long bones, in short bones and in between two layers of compact tissue of flat bones.

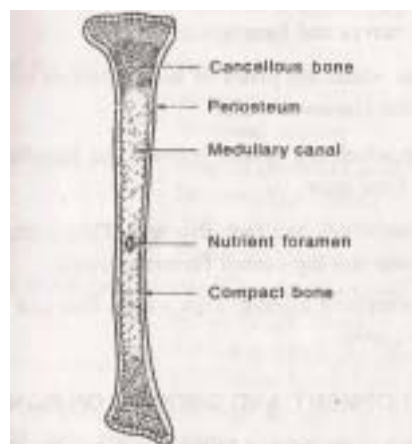


Fig. 7. A long bone (longitudinal section)

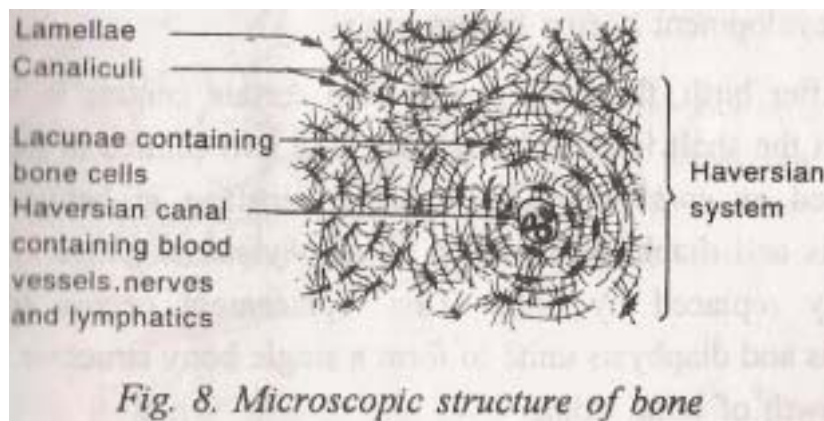
Gross structure of a long bone:

A long bone has two ends (epiphysis) connected by a shaft (diaphysis). The outer membrane covering the bone is periosteum. It is followed by a thick layer of compact bone. Inside this is a central medullary canal. Nutrient foramen is the opening through which arteries pierce the medullary canal.

Microscopic structure of bone:

Cross section of a bone under the microscope shows the following structures:

1. *Haversian canal* which lies at the centre. It contains blood vessels, nerves and lymphatics.



2. *Lamellae* which are plates of bone arranged concentrically around the Haversian canal.
3. *Lacunae* which are spaces between the lamellae and they contain bone cells.
4. *Canaliculi* which are fine channels. They radiate between the lacunae and the central *Haversian canal*.

All the structures together form a unit. This unit is called as the *Haversian system*.

DEVELOPMENT AND GROWTH OF BONES

Formation of the bone is called is *ossification*. Bones of the skeleton are developed in two ways:

- 1) Some bones develop in sheets of fibrous tissue (intra-membranous ossification)
- 2) Other bones develop in bars of cartilage (intracartilagenous ossification). In both cases, bone cells called osteoblasts

invade the area of ossification. Here, calcium salts are deposited to give the necessary hardness. This process of bone development occurs before birth.

After birth, the bone grows from certain centers in it. The centre in the shaft is called *diaphysis*. The two centers in the ends are called as *epiphysis*. The layer of cartilage in between the epiphysis and diaphysis is called as *epiphyseal cartilage*. This is gradually replaced by bone. This replacement occurs till the epiphysis and diaphysis unite to form a single bony structure. After this, growth of bone stops.

BONES OF HUMAN SKELETON:

A total of 206 bones form human skeleton. These bones can be classified as:

- | | | |
|------------------------|---|--|
| 1 Bones of the skull | : | Bones of cranium, face and lower jaw |
| 2 Bones of the trunk | : | Ribs
Sternum
Vertebral column |
| 3 Bones of upper limb | : | Scapula (shoulder girdle)
Humerus (arm bone)
Radius and ulna (forearm bones)
Phalanges (finger bones) |
| 4. Bones of lower limb | : | Pelvic girdle (hip bone)
Femur (thigh bone)
Tibia and fibula (leg bones)
Meta tarsal bones (foot bones) |

Bones of the skull and trunk form the axial skeleton. Bones of the upper and lower limbs form the *appendicular* skeleton.

BONES OF THE SKULL

Bones of the skull are divided into two groups:

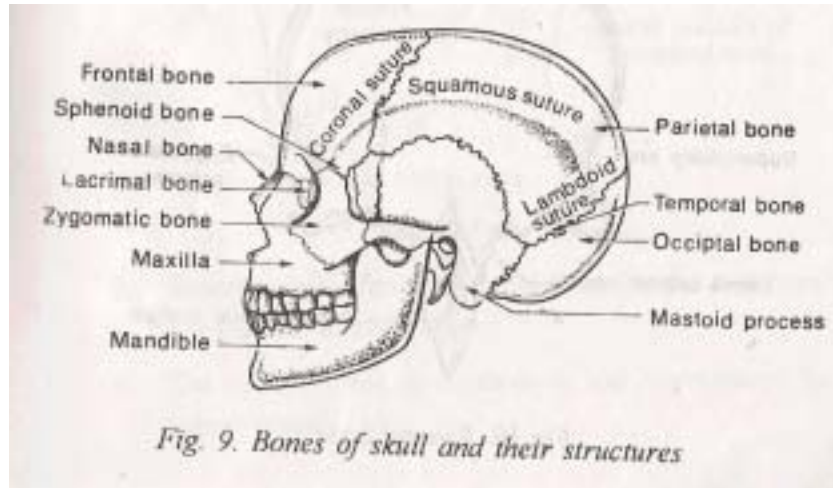
1. Bones of cranium (or brain box)
2. Bones of face

Bones of cranium :

Cranium is formed by 8 bones They are:

1. One frontal bone
2. Two parietal bones

3. Two temporal bones
4. One occipital bone



5. One sphenoid bone
6. One ethmoid bone

Sutures of the cranium :

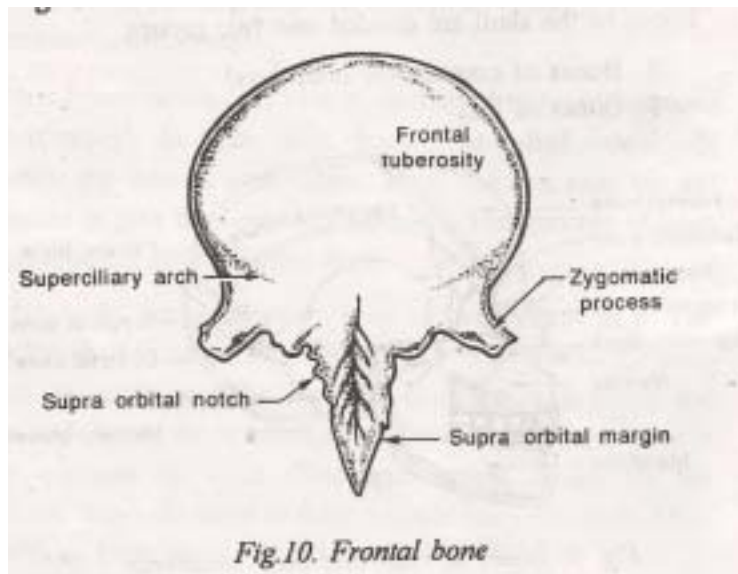
Sutures are the immovable joints which unite the bones of the skull. The important sutures are:

1. Coronal suture: between the frontal bone and the two parietal bones
2. Sagittal suture: between the two parietal bones.
3. Lambdoid suture: between the occipital bone and the two parietal bones

FRONTAL BONE:

It forms the forehead and the roof of the orbit. The features of frontal bone are:

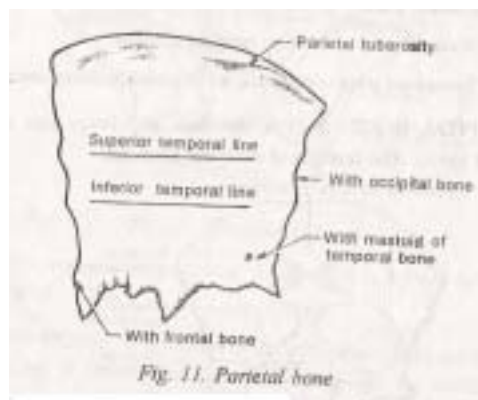
1. **Supraorbital margins** form the arches of orbit.
2. **Nasal notch** - bone projecting between supraorbital margins. Nasal bones are fitted to this.
3. **Superciliary arch**-lies above these two structures. Frontal tuberosities - the two prominences of forehead.
4. **Frontal tuberosities**-the two prominences of forehead.
5. **Frontal sinus**- a space behind the forehead. It contains air and is lined by mucous membrane.



PARIETAL BONES :

They are two in number. Both form the roof and sides of the skull. It has four' borders, four angels and two surfaces.

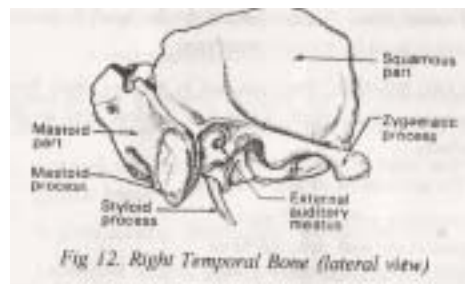
1. The articulation of this bone are anteriorly with frontal bone posteriorly with occipital bone medially with the other parietal bone below with the temporal bone
2. It contains an eminence called parietal tuberosity.
3. Superior and inferior 'temporal lines are the two lines which run parallel to each other.
4. The inner surface is concave. It has impressions for meningeal vessels.



TEMPORAL BONES:

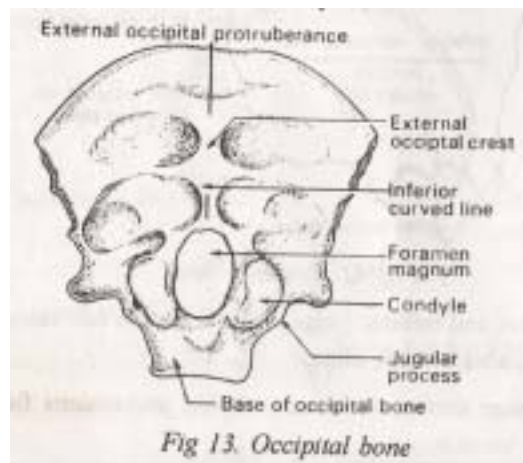
They are two in number. They form lower part of the sides of the skull. The parts of temporal bone are:

1. **Mastoid part**-contains mastoid process
2. **Squamous part**-a flat part having the zygomatic process which is connected to zygomatic bone.
3. **Petrous part**-forms the bone of the internal ear.
4. **Tympanic part**-contains the external auditory meatus.

**OCCIPITAL BONE :**

It is at the back and lower part of the cranial cavity. The features of occipital bone are:

1. A prominence above called as *external occipital protuberance*.
2. *Condyles*, two in number which articulate with atlas.



3. An opening at the base of skull called *foramen magnum*. The spinal cord passes through this opening.

SPHENOID BONE:

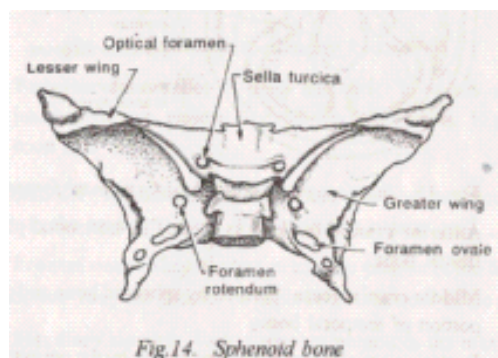
It lies at the base of the skull. It forms a large part of middle cranial fossa. It contains:

1. Two pairs of wing-like structures called "greater" and "lesser" wings.
2. "Sella turcica" or "hypophyseal fossa" which is a facet for the pituitary glands.

ETHMOID BONE :

It is cubical in shape. It is very light and thin. It is situated at the roof of nose and in between the orbits. It contains:

1. Two *labyrinths* composed of ethmoidal sinuses.
2. A *perpendicular* plate forming the upper part of nasal septum.
3. *Cribriform* plate fitting into a notch of frontal bone.
Olfactory nerves pass through perforations in this plate.

**CRANIAL FOSSAE:**

The base of the skull is divided into three **fossae**. These are:

1. **Anterior cranial fossa:**

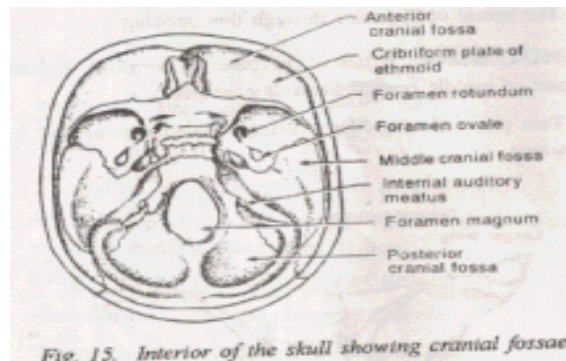
It is formed by horizontal plates of frontal bone.

2. **Middle cranial fossa:**

Formed by sphenoid bone and **petrous** portion of temporal bones.

3. **Posterior cranial fossa:**

Formed mainly by the occipital bone.



THE FONTANELLES :

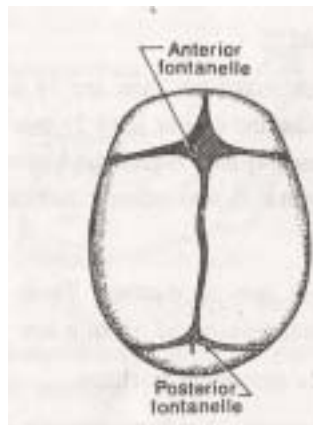
At birth, skull bones of the child are not completely ossified. The space between the bones are filled by membranes. These membranes at the angles of bones are called fontanelles. These fontanelles are:

1. **Anterior fontanelle:**

it is the largest of the fontanelles. It is diamond shaped. It is situated at the junction of frontal and two parietal bones. Here, the coronal and sagittal sutures meet. This fontanelle closes at the age of 1 year and 6 months.

2. **Posterior fontanelle:**

It is at the back. It occurs -at the junction of two parietal and the occipital bones. It closes soon after birth.



SINUSES OF THE SKULL:

These are cavities or chambers present in the bones the skull. The important sinuses are:

1. **Frontal Sinus:**

They are two in number present in the frontal bones. They are present on each side at the root of the nose.

2. Maxillary sinuses:

Two in number present in the maxillary bones. They lie on each side of the nose.

3. Ethmoidal and sphenoidal sinuses:

They are the other sinuses present in the skull. All these sinuses communicate with the nose.

Functions of sinuses

1. They give resonance to the voice.
2. They lighten the bones of face and cranium.

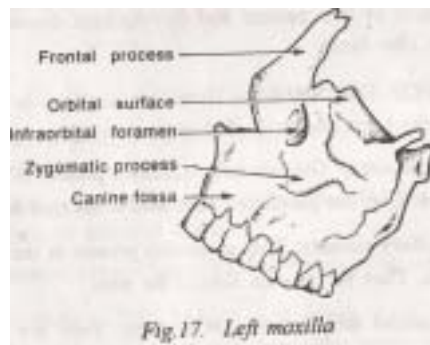
BONES OF THE FACE

The bones which make the face are 14 in number. These bones are : 1) Two maxillae (upper jaw) 2) one mandible (lower jaw) 3) two palate bones 4) two zygomatic bones 5) two lacrimal bones 6) two nasal bones 7) two inferior turbinate bones 8) one vomer

MAXILLAE:

They are two in number. These bones form the upper jaw. The essential features of maxilla are:

1. A *body* which is pyramidal in shape.
2. Four processes namely *zygomatic process* *alveolar*



process, *frontal process* and *palantine process*.

3. *Maxillary sinus* present in the internal aspect.

MANDIBLE :

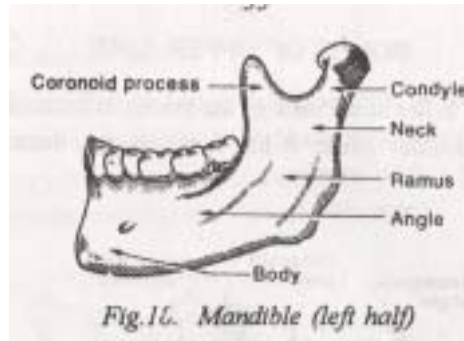
This bone forms the lower jaw and is the only movable bone of skull. It contains:

1. A *body* which is the horizontal part in the centre. It

contains the lower teeth and forms the chin.

2. Two *rami*, one on each side. Each ramus contains the *coronoid process* in the front and *condyle of jaw* (head) which lies behind.

Temporo-mandibular joint is formed by the articulation of condyle with the temporal bone



PALATE BONES:

They are two in number. They form the roof of the mouth cavity and the hard palate.

ZYGOMATIC BONES:

Two bones. They form a part of the floor of the orbit, Each of them contains a temporal process. This process joins with the zygomatic process of temporal bone and forms the zygomatic arch.

LACRIMAL BONES:

They are two bones found in the interior of the orbit. It contains the lacrimai sac which secretes the lacrimal fluid.

NASAL BONES:

They are two in number. They form the nasal bridge.

INFERIOR TURBINATE BONES:

Two in number. They are also called as nasal conchae. They are found in the interior of the nasal cavity

VOMER:

It forms the lower part of nasal septum.

HYOID BONE:

It is V shaped bone. It has:

1) a *body* 2) two horns called as *lesser horn* and greater horn. The hyoid bone is attached to the base of the tongue and to styloid process by means of ligaments.

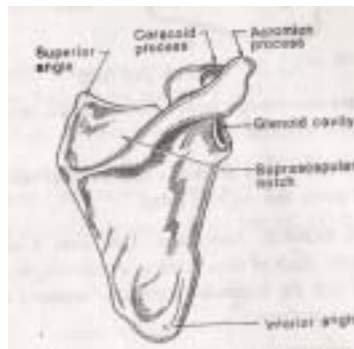
BONES OF UPPER LIMB**SCAPULA:**

It lies at the back of the thorax. It forms the posterior part of the shoulder girdle. It has two surfaces, three angles and three borders.

The surfaces of scapula are:

1. Anterior or costa! surface:

It is called as the suprascapular fossa. It lies nearest to the ribs. Subscapularis muscle is attached to this surface.

**2. Posterior or dorsal surface:**

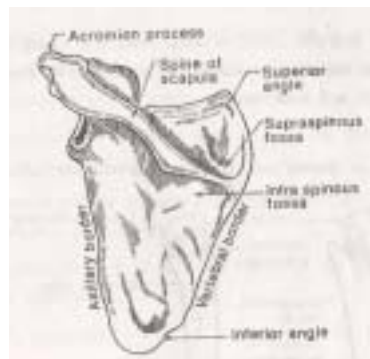It is divided into two fossae by spine of scapula which ends with acromion process. The fossae are:

- a) **Supraspinous fossa** which is the upper one. It gives attachment to supraspinatus muscle.
- b) **Infraspinous fossa** which is below. It gives attachment to infraspinatus muscle.

The borders of scapula are:

1. Superior border:

It lies in the upper part. It extends from the superior angle to the base of coracoid process. Suprascapular notch is at the inner extremity of this border. The suprascapular vessels pass through this notch.



2. Medial or vertebral border:

It is nearest to vertebral column. It extends between superior and inferior angles.

3. Lateral or axillary border:

It is nearest to axilla. It lies between inferior angle and glenoid cavity.

The angles of scapula are:

1. Superior angle:

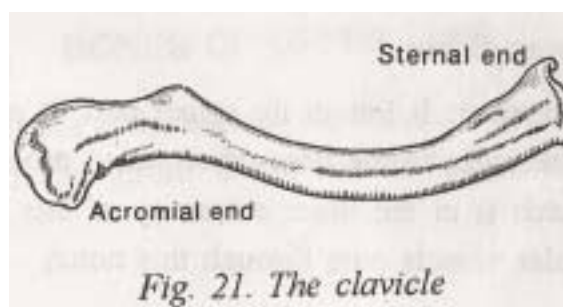
It lies at the junction between superior and medial borders.

2. Inferior angle:

It is the junction between medial and lateral borders. It is the lowest point of the scapula.

3. Lateral or external angle:

It contains glenoid cavity which receives the head of humerus (to form shoulder joint). *Corocoid* process of scapula arises internal to glenoid cavity.



CLAVICLE:

It is also called as collar bone. It is a long and curved bone. It forms the anterior part of shoulder girdle. It contains a shaft, two ends and four borders.

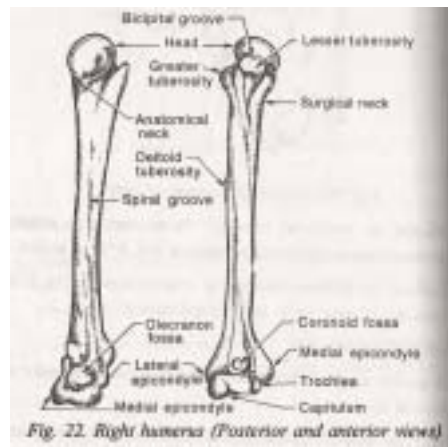


Fig. 22. Right humerus (Posterior and anterior views)

The ends are:

1. **Medial** or *sternal* end. It articulates with sternum.
2. Lateral or *acromial* end. It articulates with acromion process of scapula.

The borders of clavicle are superior, inferior, anterior and posterior borders.

HUMERUS:

It is the longest bone of upper limb. It contains two extremities and a shaft.

Upper extremity: It contains:

1. A *hemispherical head* which articulates with glenoid cavity of scapula (at the Shoulder joint)
2. *Anatomical neck* which is below the head.
3. *Greater tuberosity* which is below the anatomical neck. It is in the outer side of upper extremity.
4. *Lesser tuberosity* which is also below the anatomical neck. But it is at the front.
5. *Bicipital groove* or *intertubercular sulcus*: It lies in between these two tuberosities.
6. *Surgical neck*: It is a narrow point of the bone below the two tuberosities.

Shaft: It contains

1. *Deltoid tuberosity* which is a rough tubercle on the lateral aspect of the shaft. It receives the insertion of deltoid muscle.

2. *Spiral or radial* groove which is a oblique groove across the back of the shaft. The radial nerve passes through this groove.

Lower extremity : It contains:

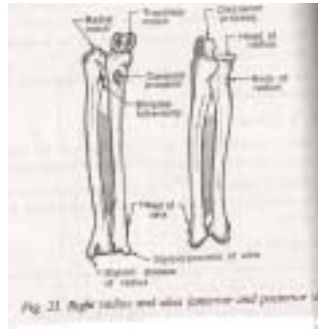1. *Trochlea* which is a pulley-shaped surface on the innerside. It articulates with hina.
2. *Capitulum* on the outer side. It articulates with radius.
3. *Coronoid fossa* which is a depression. It lies above the articulating surface for ulna.
4. *Olecranon fossa* which lies at the back. It receives the olecranon process of ulna
5. *Medial and lateral epicondyles* which lie on each side of the articulating surfaces.

ULNA :

It is the inner most bone of the forearm. It contains two extremities and a shaft.

Upper extremities: It contains:

1. *Coronoid process* which is a projection in front. It fits into the coronoid fossa of humerus.
2. *Olecranon process* which is an upward projection at the



back It fits into olecranon process of humerus.

3. Trochlear notch which is formed by these two processes. It articulates with trochlear surface of humerus.
4. Radial notch which is on the outer or lateral aspect. It articulates with head of radius.

Shaft :

It is tapering towards the lower end. It contains surfaces and borders. It gives attachment to:

1. Muscles which control movements of wrist and fingers.
2. Flexor and extensor muscles of forearm.
3. Muscles of pronation and supination of forearm

Lower extremity: It contains:

1. *Head of ulna* which is a small rounded eminence. It articulates with lower extremity of radius.
2. *Styloid process* which projects downwards from back of lower extremity.

RADIUS :

It is the lateral or outer most bone of forearm. It contains two extremities and a shaft.

Upper extremity: It contains;

1. A head which is more or less button- shaped.
2. *Neck* which lies below the head.
3. *Biceps tubercle* which lies below and to the medial side of neck. It gives insertion to biceps muscle.

Shaft:

It is narrower above and wider below. It contains surfaces which give attachment to a variety of muscles.

Lower extremity:

It contains styloid process which is on the outer or lateral aspect.

BONES OF WRIST AND HAND

Bones of Wrist:

The bones of carpus or arranged in two rows. They are

1. First or proximal row made of *scaphoid, lunate, triquetral and pisiform bones*.
2. Second or distal row made of *trapezium, trapezoid, capitate and hamate bones*.

Bones of Palm :

They are made of metacarpal bones. They are long bones which contain a head, a shaft and a base. The bases articulate

with the distal row of carpal bones. The heads articulate with the proximal row of phalanges.

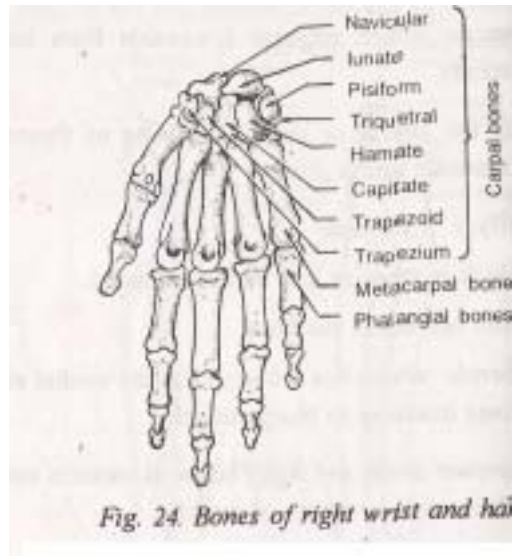


Fig. 24. Bones of right wrist and hand

Bones of fingers:

They are made of phalangeal bones. These are long bones. The thumb has two phalanges. Other fingers have three phalanges. They are proximal, middle and distal phalanges.

Metacarpo-phalangeal joints are the joints between metacarpal and phalangeal bones.

Interphalangeal joints are the joints between the phalangeal bones themselves.

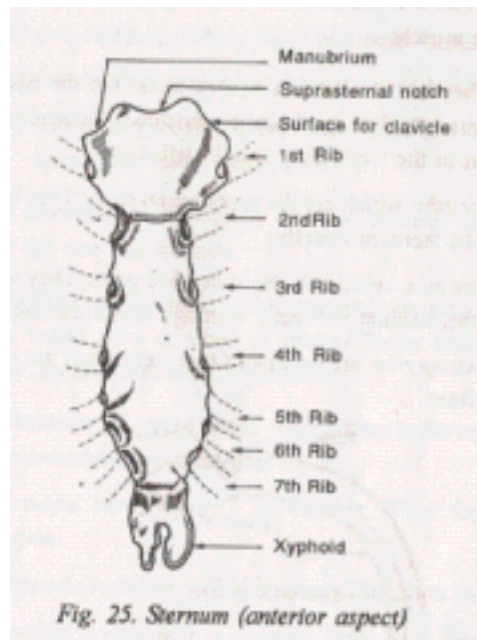
BONES OF THORAX

The skeleton of the thorax is made of the following bones:

1. **Stemum** in the front
2. Twelve parts of ribs at the sides.
3. Twelve thoracic vertebrae at the back.

STERNUM:

It is also called as breast bone. It is a flat bone which is divided into three parts namely *manubrium sterni*, *body of sternum* and *xiphoid bone*.



Manubrium sterni :

It is the upper part which is triangular in shape. It contains:

1. *Clavicular notches* on both sides. These notches articulate with clavicle.
2. *Suprasternal notch* which is present in between the two clavicular notches.
3. *Articular surfaces* 'on both sides for the first rib.

Body of sternum (gladiolas)

The second rib is attached at the junction between manubrium stemi and body of sternum. This junction is called as Angle of Ludwig. The body of sternum has attachments for 3rd, 4th, 5th, 6th and 7th ribs.

Xiphoid bone (ensiform process)

It is the lowest part of sternum. To this are attached the diaphragm, linea alba and rectus abdominis muscle.

RIBS:

They are arranged in twelve pairs, On the back side, all of them are attached to thoracic vertebrae. Depending on their attachment in the front, they are classified as:

1. True ribs which are the upper seven pairs. They are

- attached to the sternum directly.
- 2. False ribs which are the lower five pairs. They are attached to the sternum indirectly (through costal cartilages).
- 3. Floating ribs are the lowest two pairs. They are not attached in front.

A rib consists of the following parts:

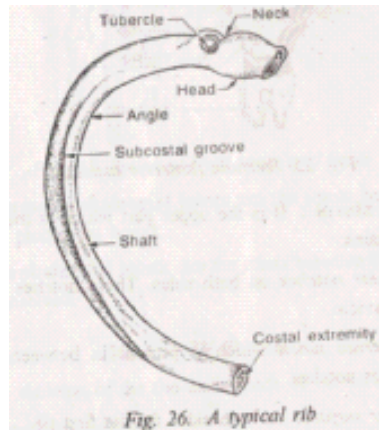


Fig. 26. A typical rib

1. **Anterior or sternal end**: It has depressions for attachment of costal cartilage.
2. **Posterior or vertebral end**: It has a head, neck and tubercle.
3. **Shaft** which has
 - a) Two surfaces namely inner and outer surfaces
 - b) Two borders namely upper and lower borders.
 - c) subcostal groove present in the inner surface. It contains intercostal vessels and nerves.

Costal cartilages:

These are bars of hyaline cartilage. They connect the ribs and sternum.

VERTEBRAL COLUMN:

The vertebral column (or spinal column) is made of a number of bones. These bones are called vertebrae. In all, there are 33 vertebrae

Classification of vertebrae: According to the region they occupy, the vertebrae are classified as

1. *Cervical vertebrae*: 7 In number. They form the neck region.

2. *Thoracic vertebrae*: 12 in number. They form back of thorax.
3. *Lumbar vertebrae*: 5 in number. They form lumbar region.
4. *Sacral vertebrae*: 5 in number. They form the sacrum.
5. *Coccygeal vertebrae*: 4 in number. They form coccyx. Except the first and second cervical vertebrae (axis and atlas), other vertebrae have similar characteristics. So these other vertebrae are called as typical vertebrae.

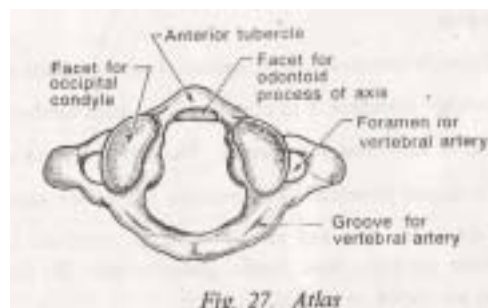
STRUCTURE OF A TYPICAL VERTEBRA: A typical vertebra (Fig.29) contains :

1. A *body* which is a box shaped anterior part. It is slightly concave in the upper and lower surface.
2. *Neural arch* which is the posterior part. It contains
 - a) two pedicles which project backward and
 - b) two *laminae* which are directed backward to meet behind in the mid-line.
3. *Two transverse processes*, one on each side. They lie in the junction between pedicle and lamina.
4. *One spinous process* which is a backward projection. It occurs where the two laminae unite in the mid-line.
5. *Two articular processes*, in the upper and lower surface. They lie at the junction between pedicle and laminae (near the transverse process).
6. *Neural canal* which is a circular opening. The spinal cord passes through this.

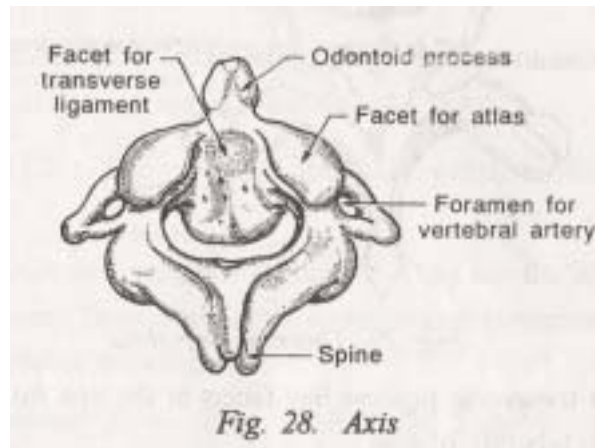
CERVICAL VERTEBRAE They are seven in number.

The first cervical vertebra is called as atlas. The second cervical vertebra is called as axis. These two cervical vertebrae have different structures when compared with others.

1. It does not have a body.



2. It does not have spinous process.
3. On the upper surface, it has two facets. These facets articulate with the condyles of occipital bone (to form atlantooccipital joint).



Axis : It is the second cervical vertebra. It contains:

1. *Odontoid process* which is an upward projection from the body. It articulates with anterior arch of atlas.
2. *Two facets* on the anterior surface. They articulate with atlas.
3. *A spine* which is small and bifid.

Other cervical vertebrae:

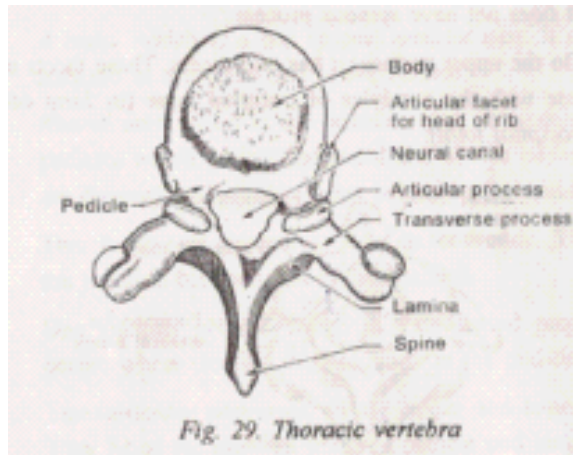
They are the lower five. Their features are: 1. a smaller body
2. oblong shape 3. triangular neural canal 4. bifid spinous process 5. vertebral foramen in the transverse process.

THORACIC VERTEBRAE:

They are twelve in number. These vertebrae carry the ribs. The characteristic features of these vertebrae are:

1. Body is heart shaped
2. Body has facets, one on each side for the attachment of head of ribs.
3. The transverse process has facets at the tips for articulation with tubercle of ribs.
4. Vertebral foramen is absent.
5. Pedicle and laminae are absent.

5. Pedicle and laminae are absent.
6. Spinous process is long and projects downwards.



LUMBAR VERTEBRAE:

They are five in number. They have the following characteristics.

1. Body is big and kidney shaped.
2. Spinous process is short, stout and directed backwards.
3. No articular facets for ribs.
4. Pedicles and laminae are present.

SACRAL VERTEBRAE :

They are five in number. All of them unite to form a single bone called sacrum. The sacrum joins with the pelvic bone and takes part in the formation of pelvic cavity. The features of sacrum are:

1. *Sacral foraminae* which are four openings present in the anterior surface. Nerves pass through these openings.
2. *Lateral masses* on either side. They are formed by the union of transverse processes.
3. *Sacral promontory* which is the projection of the upper part of sacrum.

COCCYGEAL VERTEBRAE:

They are four in number. All of them unite to form a single bone called Coccyx.

LIGAMENTS:

The vertebrae are held together by the following ligaments.

1. *Anterior and posterior ligaments*: They run the whole length of spine. They connect the anterior and posterior aspects of the bodies respectively.
2. *Ligamenta flava*: They connect the laminae of vertebral arches.
3. *Supraspinous ligaments*: They lie between the spines and connect them.
4. *Intervertebral discs*: They are made of fibrocartilage.

BONES OF THE PELVIC GIRDLE

The pelvic girdle is the connection between the trunk and lower extremities. It is formed by:

1. Two innominate bones, one on each side.
2. The sacrum and coccyx in between.

INOMINATE BONE:

It is called as pelvic bone or hip bone. It is made of three parts namely *ilium*, *ischium* and *pubis*. All these three bones unite to form a large cup shaped cavity on the outer surface called *acetabulum*. The head of femur fits into acetabulum forming the hip joint.

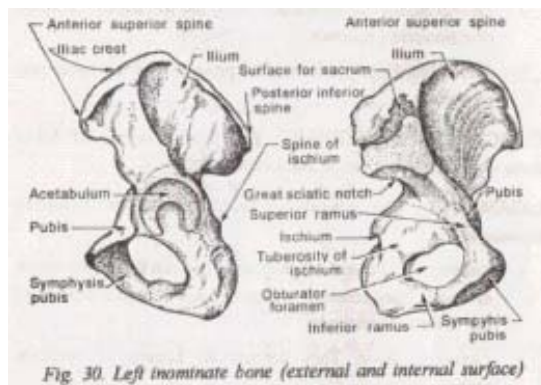


Fig. 30. Left innominate bone (external and internal surface)

Ilium :

It is the upper expanded and flat part of innominate bone. It contains:

1. External or gluteal surface:

This surface contains three ridges namely superior, middle and inferior gluteal ridges. They give attachment to gluteal muscles.

2. Internal surface which is concave.

It forms part of iliac fossa and it gives attachment to iliac muscles.

3. An upper margin called as crest of ilium. The crest of ilium contains four spines. They are:
 - a) Anterior superior iliac spine
 - b) Posterior superior iliac spine
 - c) Anterior inferior iliac spine
 - d) Posterior inferior iliac spine
4. Great sciatic notch which is below the articulating surface for sacrum.

Pubis:

It is the front portion of innominate bone. It contains:

1. *A body* which is more or less square in shape.
2. *Symphysis pubis* which is the union of the pubic bones in the front.
3. *Superior ramus* which is a bridge of bone projecting from the outer part of body and joins it to ilium.
4. *Inferior ramus* which is the lower part of the body and joins it to ischium.

Ischium :

It is the solid, broad portion at the lower and back part of innominate bone. It contains:

1. A body which forms acetabulum on the outer surface.
2. Tuberosity of ischium present at the lowest point. It supports the body weight while sitting.
3. Spine of ischium which arises from the back of ischium.

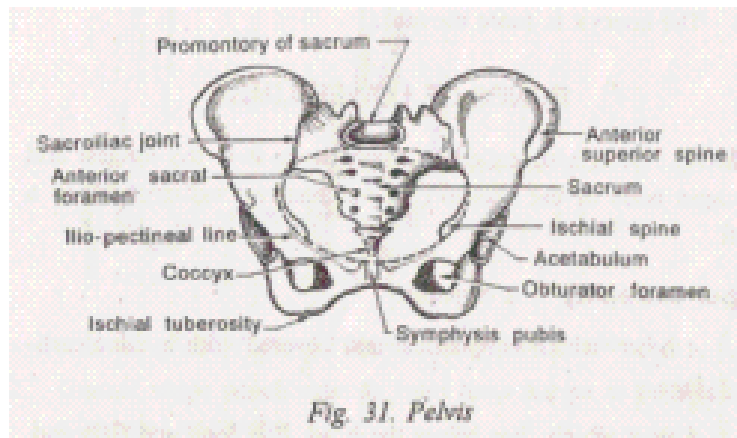
Obturator foramen is a roughly triangular opening which is bounded by:

1. Public bone in front and above.
2. Ischium behind and below.

PARTS OF PELVIS : Pelvis can be divided into:

1. *False pelvis* which is the upper part. It is formed by the two iliac bones.
2. *True pelvis* which is the lowest part. It is formed by ischium and pubis (in the front and on each side) and by sacrum (behind).

Pelvic brim is the upper opening of true pelvis



Iliopectineal line is the line present at the junction of ilium with ischium.

Differences between female and male pelvis

The female pelvis is adapted for pregnancy and child birth. It differs from male pelvis in the following aspects.

1. It is shallow and wider than male pelvis.
2. Inlet and outlet are longer and nearly oval in shape.
3. Bones are lighter and smoother.
4. Pubic arch is wider.
5. Ischial tuberosities are further apart.
6. The coccyx is more movable.

BONES OF LOWER LIMB

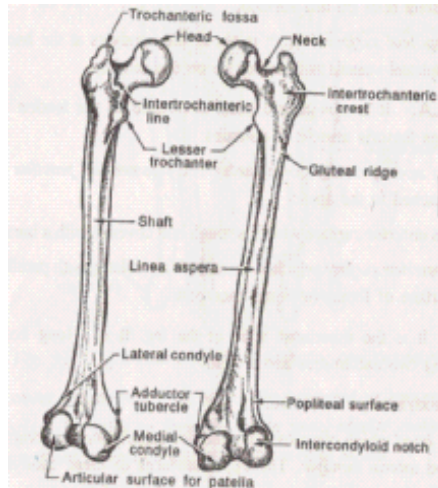
FEMUR: It is also called as thigh bone. It is the longest and strongest bone of the skeleton. It contains two extremities and a shaft.

Upper extremity: It contains:

1. A head which is spherical and covered with hyaline cartilage.
2. A neck which lies below the head. It is long and flattened.
3. Greater trochanter which is on the outer side where the neck joins the shaft.
4. Lesser trochanter which is on the inner side where the neck joins the shaft.
5. Anterior and posterior intertrochanteric lines are two lines which unite greater and lesser trochanters.

Shaft : It is smooth, cylindrical and rounded in front and at the sides. It contains:

1. Linea aspera which is a ridge on the posterior aspect



2. Gluteal ridge which extends from linea aspera to the back of greater trochanter.

3. Spiral line which extends at the inner aspect from linea aspera to lesser trochanter

Lower extremity: It contains:

1. *Medial and lateral condyles* lying one on each side.
2. *Intercondylar notch* which lies behind. It separates these two condyles.
3. *Adductor tubercle* which is a small tubercle above the medial condyle.
4. *Patellar surface* which separates the two condyles in front. Patella rests on this surface.
5. *Popliteal surface* which is above the condyles at the back. Popliteal vessels and nerves lie on this surface.

PATELLA:

It is a sesamoid bone developed in the tendon of quadriceps femoris muscle. It contains:

1. An apex pointing downwards. The ligamentum patellae is attached to the apex.
2. An anterior surface which is rough and covered with a bursa.
3. Posterior surface which is smooth. It articulates with

patellar surface of femur (to form knee point).

TIBIA:

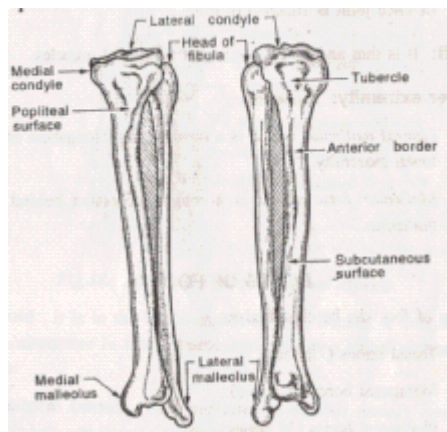
It is the innermost bone of the leg. It is a long bone containing two extremities and a shaft.

Upper extremity: it contains:

1. A *head* which contains two condyles namely *medial condyle* and lateral condyle. The upper surfaces of these condyles articulate with the corresponding condyles of femur.
2. *Popliteal notch* which separates the two condyles at the back.
3. *Tubercle of tibia* which lies below the condyles in the front.

Shaft:

It is triangular in shape having three borders and three surfaces. The shaft contains:



1. *Crest of tibia* which is present in the middle third of the anterior border.
2. *Soleal line* which is a strong ridge of bone present in the posterior surface.

Lower extremity:

It is slightly expanded. it has, an arti surface for talus to form the ankle joint. *Medial malleolus* is a downward projection present in the medial aspect.

FIBULA:

It is the lateral or outermost bone of the leg. It is a long and slender bone. It contains two extremities and a shaft.

Upper extremity: It contains:

1. *A head* which is expanded. It articulates with the back of lateral condyle of tibia. It does not take part in the formation of knee joint.

2. *Styloid process* present in the apex of head. One ligament of knee joint is attached to this.

Shaft: It is thin and gives attachment to several muscles.

Lower extremity: It contains:

1. *Lateral malleolus* which is a downward prolongation of the lower extremity.

2. *Malleolar fossa* which is a rough depression behind the malleolus.

BONES OF FOOT

Bones of foot can be classified as:

1. Tarsal bones (7 bones)
2. Metatarsal bones (5 bones)
3. Phalangeal bones (14 bones)

TARSAL BONES:

They include *calcaneum*, *talus*, *navicular*, *cuboid* and three *cuneiform bones*.

Calcaneum:

It is the largest bone of the foot. It lies at the back of foot. Above, it articulates with talus and in front with cuboid. Calcaneum gives attachment to *tendo calcaneus* of calf muscle.

Talus:

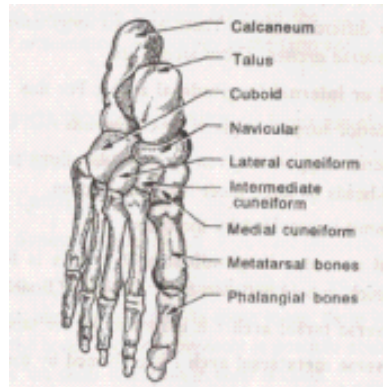
It forms the central and highest point of foot. It articulates at the sides with medial and lateral malleoli and below with calcaneum.

Navicular (or scaphoid):

It is a disc shaped bone. It is present in the medial aspect of foot. It lies between talus at the back and three cuneiform bones in front.

Cuboid:

It is in the lateral aspect of foot. Behind, it articulates with



calcaneum. In front, it articulates with two lateral metatarsal bones.

Cuneiform bones:

They are three in number namely medial, intermediate and lateral cuneiform bones. Posteriorly they articulate with navicular bone. Anteriorly they articulate with three metatarsal bones.

METATARSAL BONES:

They are five in number. They correspond with the five toes. All of them are long bones. They contain a head, shaft and base. The first metatarsal is thick and stout.

The first metatarsal is thick and stout.

The second metatarsal is longer than others.

The fifth one has a projection at the lateral side of the base.

PHALANGES:

They are 14 bones, two for the first toe and three for the rest. All of them are long bones.

ARCHES OF FOOT:

In the foot, the bones are so arranged that there are four different arches. There are two *longitudinal arches* and two *transverse arches*. These arches are

a) Medial or internal longitudinal arch: For this

1. Posterior support is given by calcaneum.

2. Anterior support is given by navicular, three cuneiforms and heads of three inner metatarsal bones.

3. Summit is provided by the talus.

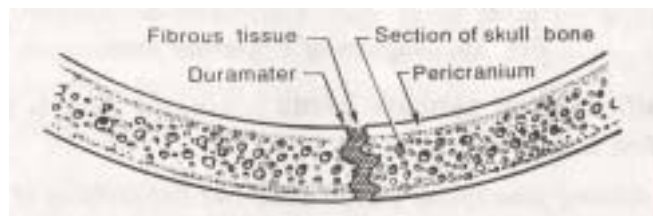
b) Lateral or outer longitudinal arch : This is formed by calcaneum, cuboid and two outer metatarsal bones.

c) Transverse tarsal arch It is formed by the tarsal bones.

d) Transverse metatarsal arch: It is formed by the heads of metatarsal bones

3. ARTHOLOGY

Any connection between bones of the skeleton is called as a *joint or articulation*. *Arthrology* is the term applied for the study of joints.



CLASSIFICATION OF JOINTS: Joints are classified as:

1. Fibrous joints
2. Cartilagenous joints
3. Synovial joints

FIBROUS JOINTS (or Synarthroses) :

They are also called as fixed or immovable joints. In these joints, there is a tight union between the bones. So no movement is possible at these joints e.g. sutures of the skull and teeth in their sockets.

CARTILAGENOUS JOINTS (or amphiarthroses):

They are also called as movable joints. In this type

1. The articular ends of the bones are covered by hyaline cartilage.
2. There is a pad of fibrocartilage between the joint.
3. The joint is covered by ligaments.

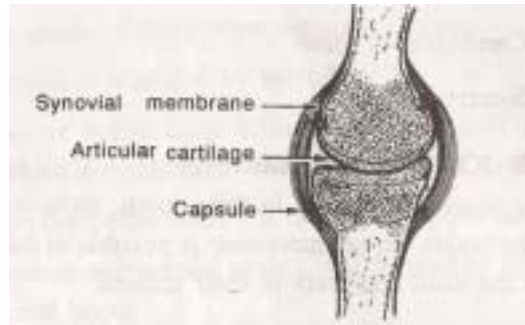
Symphysis pubis and intervertebral joints are examples of cartilagenous joints.

SYNOVIAL JOINTS (or diarthroses) : They are also called as freely movable joints. The characteristics of these joints are:

ARTHOLOGY

43

1. Articular ends of bones are covered by hyaline cartilage.
2. Bones are bound together by ligaments.
3. Joint is enclosed by fibrous capsule.
4. Capsule of the joint is lined by synovial membrane.
5. The cavity of the joint contains synovial fluid.



1. Gliding joint (plane joint): Here two flat surfaces of bones glide on each other, e.g. joint between carpal and tarsal bones.

2. Hinge joint: Here, movement is possible in one plane only e.g. elbow joint.

3. Pivot joint: In this joint, rotation is the only possible movement, e.g. joint between radius and ulna.

4. Ball and socket joint: Articular end of one bone is ball like. It fits into the socket like cavity of another bone. Movement in all directions is possible in this type e.g. shoulder joint and hip joint.

5. Condyloid joint: It is similar to hinge joint but movement occurs in two planes e.g. wrist joint.

6. Saddle joint: It has one concave surface. This results in free movement in all directions e.g. joint between metacarpal bone of thumb and trapezium.

MOVEMENTS OCCURRING AT JOINTS:

The movement which occur at joints are classified into three major types

- 1) Gliding movements
- 2) Angular movements
- 3) Rotation or circular movements

Gliding movements:

They occur when two flat surfaces move on each other. e.g. movements between carpal and tarsal bones.

2. Angular movements.

They bring about an increase or decrease in the angle between bones. Depending on the direction in which the movement occurs, they are further classified into

i) Flexion:

A movement where similar surfaces come nearer to each other. This reduces the angle between two bones e.g. bending the forearm at elbow.

ii) Extension

A movement where similar surfaces go apart. Here the angle between two bones is increased. It is the opposite of flexion e.g. straightening of the bent forearm.

iii) Adduction :

A movement which brings the limb towards midline.

iv) Abduction : It is the opposite of adduction. 'The limb is drawn away from the mid line.

3. Rotation or circular movements:

They occur when one bone moves around or within another bone. The movement occurs around a central axis. It is further classified into

i) *Medial rotation* which occurs towards medial direction.

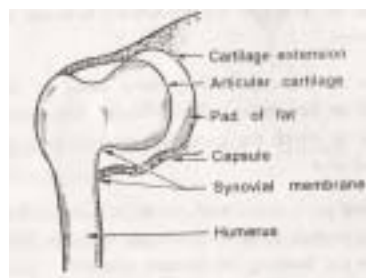
ii) *Lateral rotation* which occurs towards lateral direction.

Circumduction is a combination of rotation and angular movements. It involves flexion, abduction, extension, adduction and some rotation. This movement occurs in shoulder, hip etc.

JOINTS OF UPPER LIMB

Sterno-clavicular joint :

It is a gliding joint between sternum and clavicle. A pad of cartilage is present in the joint cavity between the bones.



Acromio-clavicular joint :

Formed by outer end of clavicle articulating with acromion process of scapula. There is a pad of cartilage between the ends of bones. There is a limited amount of movement in all directions.

Shoulder joint :

It is a ball and socket type of joint. It occurs between head of humerus and glenoid cavity of scapula. The bones are united together by ligaments. These ligaments form a very loose capsule. Also, the shoulder joint has a synovial cavity. The tendon of long head of biceps passes through this.

Movements :

All types of movements like flexion, extension, abduction, adduction, rotation and circumduction are possible at this joint.

Elbow joint :

It is a hinge joint. It is formed by humerus above and radius and ulna below. It is composed of two different joints They are

1. *Humero-ulnar joint* formed by trochlear notch of ulna and trochlear surface of humerus.

2. *Humero-radial joint* formed by head of radius and capitulum of humerus.

These four articulating surfaces are covered by a joint capsule.

Movements:

Flexion and extension occur at this joint.

Radio - ulnar joint :

This is formed by the articulation of radius and ulna at their upper and lower extremities. The interosseous membrane joins them throughout their shaft. This joint is further classified as

1. Superior radio-ulnar joint formed by head of radius and radial notch of ulna

2. Inferior radio-ulnar joint formed by head of ulna and lower end of radius.

Movements:

Pronation and supination occur at these joints.

Wrist joint:

It is a condyloid joint. It is formed by the lower end of radius and three carpal bones (navicular, lunate and triquetral).

Movements :

Flexion, extension, abduction and adduction are the movements which occur at this joint.

Metacarpo- phalangeal joints :

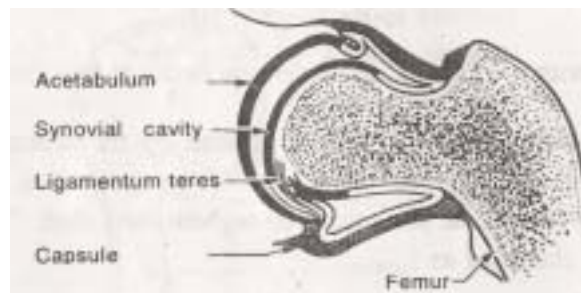
They occur between meta carpal and phalangeal bones. The movements at these joints are flexion, extension, adduction and abduction.

Interphalangeal joints :

They occur between phalangeal bones of the same finger. Flexion and extension are the movements possible.

JOINTS OF LOWER LIMB**Hip joint :**

It is a ball and socket type of joint. It occurs between acetabulum of inominate bone and head of femur. The acetabulum is deepened by a ring of fibro **cartilage called acetabular labrum**.



The joint capsule is strengthened by three ligaments. They are

1. *ilio-femoral ligament* in the front.
2. *pubo-femoral ligament* below.
3. *ischio-femoral ligament* at the back. The head of femur is connected to the sides of acetabular by means of a ligament. It is called as ligamentum leres.

Movements:

Flexion, extension, abduction, adduction, rotation and circumduction occur at this joint.

KNEE JOINT: It is a hinge joint formed by

1. Two condyles of femur articulating with the condyles of tibia
2. patella.

The structures of knee joint are

1. *Medial and lateral semi lunar cartilages:* They are attached to the upper surface of tibia. They deepen the articular surface.

2. *Cruciate ligaments :* Upper attachment is intercondylar notch of femur. Lower attachment is the upper surface of tibia. They receive blood from smaller arteries (*arterioles*) and deliver

The capsule of the joint is strengthened by medial and lateral ligaments.

Movements

1. Dorsiflexion (bending the foot up towards the leg).
2. Plantar flexion (bending the foot downwards).

JOINTS OF THE FOOT: They are:

1. Tarsal joints:

They occur between talus and calcaneum and also between other tarsal bones.

2. Tarso-metatarsal joints:

Occur between tarsal and metatarsal bones.

3. Metatarso phalangeal joints:

Occur between metatarsal and phalangeal bones.

4. Inter phalangeal joints:

They occur between phalangeal bones themselves.

JOINT DISORDERS

ARTHRITIS:

It is an inflammation occurring at a joint or joints. It can occur at any age but commonly occurs in middle and old age groups. The common type of arthritis are

- 1) Rheumatoid arthritis
- 2) Osteo - arthritis.

Rheumatoid arthritis:

It is a polyarthritis. It is bilateral and symmetrical in distribution. The commonly affected joints are those of hands and feet. In severe cases, most of the synovial joints are involved. The cause for rheumatoid arthritis is not known. It is an autoimmune disease initiated by microbial infection, probably viruses. As the disease progresses, it leads to intermittent fever. Later, there is deformity of joint leading to decrease in movement and pain. Steroids are usually given to treat this condition.

Osteoarthritis:

It is a disease occurring due to degenerative changes in the cartilages of joints. The articular cartilage becomes thinner. So the articular surfaces of bones come in contact with each other. Later the bones start degenerating. This produces pain, stiffness and decrease in movement. Physiotherapy and reduction in body weight are advised in this condition. Also steroids are beneficial.

Gout:

It is caused by the deposition of sodium urate crystals in joints and tendons. It occurs in people with high uric acid levels due to overproduction or decreased excretion by the kidneys. There is arthritis lasting for several days or weeks with some remission in between. After repeated attacks, permanent damage may occur. Joints commonly affected are ankle, wrist, knee and elbow.

DISLOCATIONS:

A dislocation is a complete separation of joint surfaces due to tearing of the joint capsule. Dislocation commonly occurs at

shoulder and hip joint.

Shoulder joint:

It is more liable for dislocation than any other joint because of:

1. Shallow articulating cavity
2. Large size of the head of humerus
3. Laxity of the capsular ligament

Dislocation of shoulder joint may complicate fractures of upper extremity of humerus.

Sternoclavicular joint:

A forward or backward dislocation may occur as a result of a heavy fall on the shoulder e.g. horse riding.

Elbow joint:

Backward dislocation can occur at elbow joint. It may be accompanied by fracture of the coronoid process.

Hip joint:

Dislocation of hip joint may occur in any direction. But backward and medial dislocation is more common since the capsule is weak at these sites. Forward dislocation is rare since the iliofemoral ligament crossing the front of hip joint is very strong. Congenital dislocation of hip joint may also occur.

Knee joint:

Knee joint is surrounded by strong ligaments and powerful muscles. So it is one of the strongest and most stable joints in the body. So dislocation of knee joint is very rare. But the following disorders may occur at knee joint.

1. Slipped cartilage:

It occurs due to tearing, detachment or displacement of one of the *semilunar cartilages* of knee joint.

2. Acute synovitis :

It may occur at knee joint due to trauma. Since the synovial membrane of the knee joint is extensive, swelling occurs on each side above the patella.

3. Bursitis:

Enlargement and inflammation of one of the bursae may occur. The bursa between patella and skin is mostly affected.

4. MYOLOGY

THE MUSCULAR SYSTEM

The muscular system consists of a large number of muscles (more than 300). They bring about various movements in the body. Muscles are attached to bones, cartilages, ligaments, skin or other musices by fibrous structures called tendons or aponeurosis. Tendon is a cord like structure whereas aponeurosis is a strong fibrous sheet. Muscles are richly supplied by blood vessels and nerves.

Each muscle has an origin and an insertion. Origin is the end which remains stationary when the muscle contracts. The end which moves is called insertion. But it is not the same in all cases. In some cases, both ends of the muscle may move. The important muscles of the body are described in the following pages.

TYPES OF MUSCLES

The muscles are of three types, skeletal, smooth and cardiac. The character of each type are summarised below :

a. Skeletal Muscles (Striped, Striated, Somatic or Voluntary Muscles)

1. These muscles are most abundant, found attached to skeleton
2. Exhibit cross - striations under microscope, and are considered to be the best differentiated form of muscle.
3. Are supplied by somatic (cerebrospinal) nerves, and therefore, are under voluntary control, with certain exceptions.
4. Respond quickly to stimuli, being capable of rapid contractions, and, therefore, get fatigued easily
5. Help in adjusting the individual to external environment.
6. are under highest nervous control of cerebral cortex, and
7. Each muscle fibre is a multinucleated cylindrical cell, containing groups of myofibrils (Cohnheim's areas) which, in turn, are made up of myofilaments of three types (myosin, actin and tropomyosin), the actual contractile elements. Examples : Muscles of limbs and body wall, and bronchial muscles.

Smooth Muscles (Plain, Unstriated, Non-striated, Visceral, or Involuntary Muscles)

1. These muscles often encircle or surround the viscera
2. do not exhibit cross striations under microscope, being plain and smooth in form.
3. are supplied by autonomic nerves, and therefore, are not under voluntary control
4. respond slowly to stimuli, being capable of sustained contraction and therefore do not fatigue easily
5. provide motor power of regulating the internal environment, related to digestion, circulation, secretion and excretion
6. are less dependent on nervous control, being capable of contracting automatically, spontaneously and often rhythmically, and
7. each muscle fibre is an elongated, spindle - shaped cell, with a single nucleus placed centrally, the myofibrils. show longitudinal striations. Ex : Muscles of the blood vessels, and the arrector pili muscles of the skin.

CARDIAC MUSCLES

1. It forms myocardium of the heart,
2. it is intermediate in structure, being striated and at the same time involuntary,
3. it is meant for automatic and rhythmic - contractions and
4. each muscle fibre, having a single nucleus placed centrally, branches and anastomoses with the neighbouring fibres at intercalated discs (apposed cell membranes), the cross striations are less prominent than those in the skeletal muscle.

MUSCLE SPINDLES (NEUROMUSCULAR SPINDLES)

Are spindle shaped sensory end organs of the skeletal muscle. Each spindle contains 6-14 intrafusal muscle fibres which are of two types, the larger nuclear bag fibres, and the smaller nuclear chain fibres. The spindle is innervated by both the sensory and motor nerves. The sensory endings are of two types, the primary sensory endings (annulospiral endings) around the central nuclear region

of the intrafusal fibres, and the secondary sensory endings (flower spray endings) beyond the nuclear region on either side of these fibres. The motor nerve supply of the spindle is derived from gamma motor neurons of the spinal cord, which from both the "en plaque" and "en grappe" terminals. Muscles spindles act as stretch receptors. They record and help regulate the degree and rate of contraction of the extrafusal fibres by influencing the alpha neurons. Recent evidence shows that the spindle activity is represented in the sensory cortex, which plays a part in conscious appreciation of the position and movements of the joints.

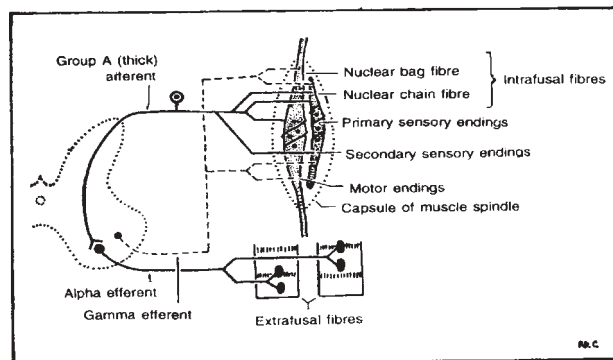


Fig. 4.11. Structure and nerve supply of the muscle spindle.

UPPER LIMB

SUPERFICIAL MUSCLES OF BACK

Which Connected upper limb to vertebral column

<i>Origin</i>	<i>Insertion</i>	<i>Nerve Supply</i>	<i>Action</i>
1. Trapezius			
Middle 1/3 rd of superior nuchal line of occipital bone . Ligamentum nuchae Spinous process & interspinous ligament of T ₁ -T ₁₂ .	Upper Posterior border of lateral 1/3 rd of clavicle. Middle - Medial border of acromion and upper lip of crest of spine of scapula lower Deltoid tubercle at medial end of spine of scapula.	Motor -Spinal accessory Proprioceptive - ventral rami of C ₃ and C ₄ .	- Rotate the scapula - Elevate scapula (along with levator scapular) - Retract scapula (along with Rhomboids)

2. Latissimus Dorsi

Lower six thoracic spines and supra spinous ligament All lumbar and sacral vertebrae Outer lip of iliac crest. Inferior angle of scapula	Floor of intertubercular sulcus of humerus	Thoraco-dorsal (C ₆ , C ₇ , C ₈)	Extends shoulder joint. Adduction Elevates Trunk during climbing Costal fibres for inspiration rest for expiration
---	--	--	---

3. Levator Scapula

Posterior tubercles of transverse processes of upper	Medial or vertebral border from upper angle to apex of	Ventral rami of C ₃ , C ₄ .	Elevates Scapula
--	--	---	------------------

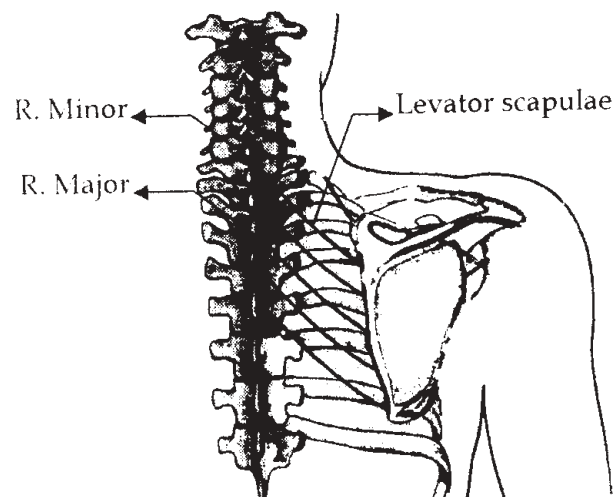
four cervical vertebrae	scapular spine.		
-------------------------	-----------------	--	--

Rhomboidus Major

Spinous process	Dorsal aspect of medial border of scapula from inferior angle to root of spine.	Dorsal Scapular C ₅ .	Retract Scapula depress shoulder
-----------------	---	----------------------------------	----------------------------------

R.Minor

Ligmentum nuchae and spinous process of C ₇ and T ₁ .	Medial border of scapula at apex of spine.	Dorsal Scapular C ₅ .	Retract scapula depress shoulder
---	--	----------------------------------	----------------------------------



MUSCLES OF PECTORAL REGION

Which connect upper limb to thorax

<i>Origin</i>	<i>Insertion</i>	<i>Verve Supply</i>	<i>Action</i>
<i>Pectoralis major</i>			
Clavicular head Medial half of anterior surface of clavicle. Stermocostal head - Lateral part of Anteral part of Anterior surface of sternum upto 6 th costal cartilage 2 nd - 6 th costal cartilage. Aponeurosis of external oblique.	As bilaminar tendon into lateral lip of intertubercular sulcus of humerus	Medial (C ₈ , T ₁) Lateral (C ₅ , C ₆ , C ₇) Pectoral nerves.	Medial rotation and adduction of Shoulder joint Clavicular -flexion Stermocostal head - extension to bring the flexed humerus to side. Accessory Inspiratory muscle

MUSCLES OF SHOULDER

<i>Origin</i>	<i>Insertion</i>	<i>Verve Supply</i>	<i>Action</i>
<i>1.Deltoid</i>			
Anterior border and superior surface of lateral 1/3 rd of clavicle Acromial lateral margin.	Deltoid tuberosity on lateral surface of shaft of humerus	Axillary nerve C ₅ , C ₆ .	Abduction Clavicular fibers - flexion, adduction + medial rotation of shoulder joint.

Lower edge of crest of scapular spine.			Posterior fibres - extension, adduction + lateral rotation of arm.
--	--	--	--

2. Subscapularis

Subscapular fossa medial 2/3 rd	Lesser humeral tubercle front of articular capsule	Upper and lower sub - scapular nerve C ₅ , C ₆ , C ₇	Medial rotator of arm
--	--	---	-----------------------

3. Supraspinatus

Medial 2/3 rd of supraspinous fossa and supraspinous fascia	Highest facet of greater humeral tubercle	Suprascapular nerve C _{4,5,6} .	Initiates abduction upto 15°. - Stabilises shoulder joint
--	---	--	---

4. Infraspinatus

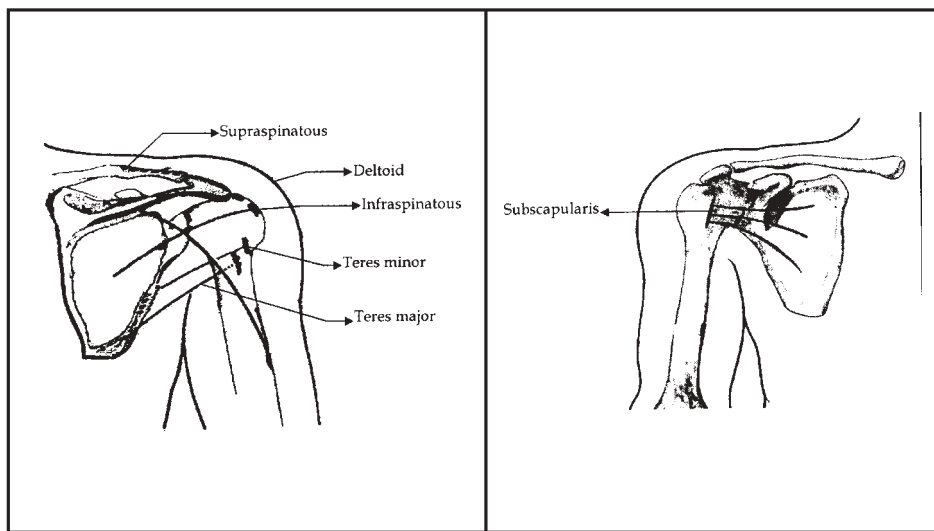
Medial 2/3 rd of lateral border on dorsal surface of scapula	Medial facet of greater humeral tubercle	Suprascapular nerve C ₄ , C ₅ , C ₆	Lateral rotator of shoulder Assists abduction
---	--	--	--

5. Teres minor

Upper 2/3 rd of lateral border on dorsal surface of scapula	Lowest facet of greater humeral tubercle	Axillary nerve C ₄ , C ₅ , C ₆	Lateral rotator of humerus abduction of shoulder joint
--	--	---	---

6. Teres major

Dorsal oval area near the inferior scapula angle.	Medial lip of the humeral intertubercular sulcus	Lower subscapular nerve C ₆ , C ₇	Medial rotator and extension of arm
---	--	--	-------------------------------------



MUSCLES OF ARM

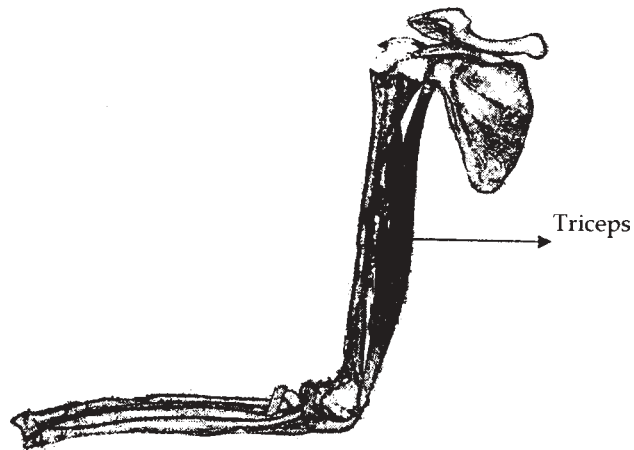
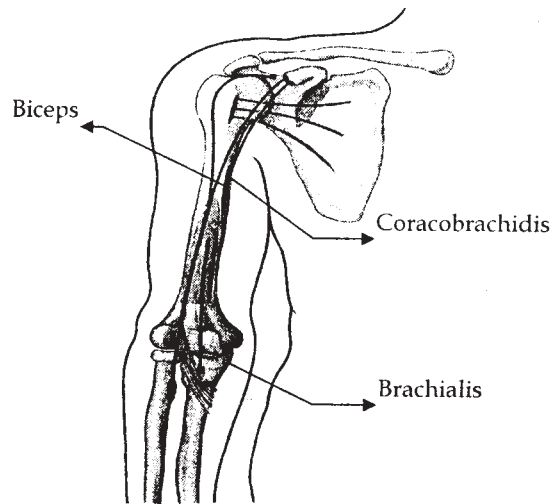
<i>Origin</i>	<i>Insertion</i>	<i>Nerve Supply</i>	<i>Action</i>
1. Biceps brachii			
Short head - Tip of coracoid process Long head - supra glenoid tubercle of scapula and adjacent glenoid labrum	Posterior part of radial tuberosity Bicipital aponeurosis into posterior border of ulna	Musculocutaneous nerve C ₅ , C ₆ , C ₇	Supination Flexion of elbow joint Long head keeps the humeral head in glenoid cavity during abduction of shoulder joint.

2.Brachialis

Anteromedial and anterolateral surface of lower half of shaft of humerus Medial intermuscular septum	Anterior surface of coronoid process and tuberosity of ulna	Musculocutaneous radial C ₇	Flexion of elbow joint
---	---	---	------------------------

3.Triceps

Long head - infraglenoid tubercle of scapula lateral - oblique posterior ridge on humeral shaft Lateral - intermuscular septum Medial - Posterior surface of shaft of humerus, medial border of humerus, medial and lateral intermuscular septum	Posterior part of upper surface of olecranon process	Radial nerve C ₆ , C ₇ , C ₈	Extensor of elbow joint Adducts the humerus to thorax
--	--	--	--



MUSCLES OF FOREARM

<i>Origin</i>	<i>Insertion</i>	<i>Nerve Supply</i>	<i>Action</i>
<i>1. Pronator teres</i>			
Humeral head - Lower part of medial supracondylar ridge medial epicondyle Ulnar - medial side of coracoid process.	Middle of the lateral surface of shaft of radius	Median nerve C ₆ , C ₇	Pronation of forearm, weak flexor of elbow joint

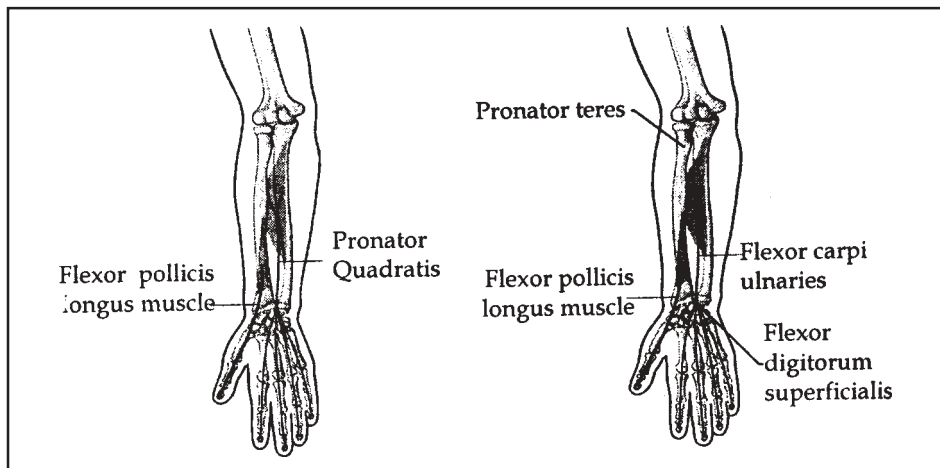
2. Flexor carpi ulnaris

Humeral - medial epicondyle Ulnar - medial margin of olecranon process and upper 2/3 rd of posterior border of ulna	Pisiform Hook of hamate and base of 5 th metacarpal through pisohamate and pisometacarpal ligament	Ulnar nerve C ₇ , C ₈	Flexor of wrist adduction at wrist joint
---	---	---	--

DEEP FLEXOR MUSCLES

<i>Origin</i>	<i>Insertion</i>	<i>Nerve Supply</i>	<i>Action</i>
<i>1. Flexor digitorum profundus</i>			
Anterior and medial surface of upper 3/4 th of shaft of ulna Adjacent interosseous	4 tendons into palmar surface of base of distal phalanges	Medial part by ulnar Lateral by anterior interosseous branch of median	Flexes the terminal phalange

membrane Upper 3/4 th of posterior border of ulna		nerve	
---	--	-------	--



POSTERIOR COMPARTMENT OF FOREARM

<i>Origin</i>	<i>Insertion</i>	<i>Nerve Supply</i>	<i>Action</i>
1.Brachio radialis			
Upper 2/3 rd of lateral supra condylar ridge lateral inter muscular septum	Base of styloid process of radius	Radial nerve	Flexor of elbow joint

2.Extensor carpi radialis longus

Lower 1/3 rd of the lateral supracondylar ridge lateral inter muscular septum	Dorsal surface of base of 2 nd metacarpal	Radial nerve	Extension of wrist abduction
--	--	--------------	------------------------------

3. Extensor Digiti minimi

Lateral epicondyle of humerus	Dorsal digital expansion of little finger	Posterior interosseous nerve of radial C ₇	Extensor of joint of little finger and wrist
-------------------------------	---	---	--

4. Extensor carpi ulnaris

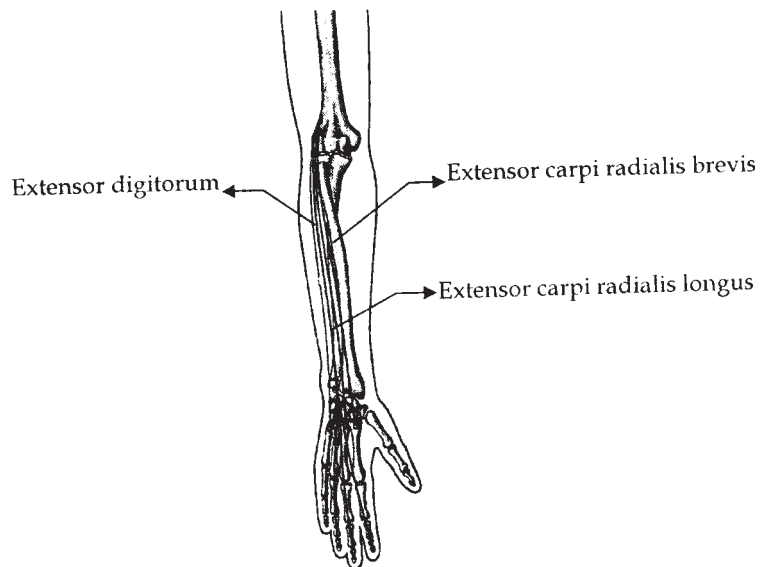
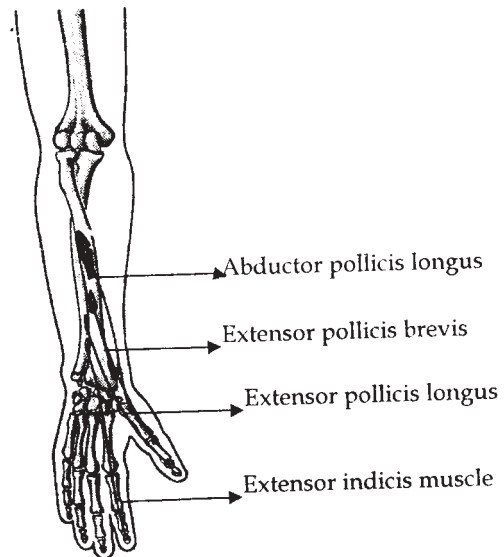
Lateral epicondyle of humerus posterior border of ulna aponeurosis	Tubercle on the medial side of base of 5 th metacarpal bone	Posterior interosseous nerve of radial C ₇	Extensor and adduction of wrist
--	--	---	---------------------------------

DEEP GROUP MUSCLES

<i>Origin</i>	<i>Insertion</i>	<i>Nerve Supply</i>	<i>Action</i>
1. Supinator			
Lateral epicondyle Radial collateral ligament, Annular ligament Supinator crest of ulna	Upper 1/3 rd of lateral surface of radius -Between anterior and posterior oblique lines	Posterior interosseous nerve	Supination in extended elbow

2. Abductor

Pollicus longus posterior surface of radius & ulna, interosseous membrane	Radial side of base of first metacarpal	Posterior interosseous nerve	Abductor and extensor of thumb
---	---	------------------------------	--------------------------------



MUSCLES OF HAND - THENAR

<i>Origin</i>	<i>Insertion</i>	<i>Nerve Supply</i>	<i>Action</i>
1. Flexor pollicis brevis			
Superficial - flexor retinaculum and tubercle of trapezium deep - Trapezoid and capitate bones	Radial side of base of proximal phalanx	Recurrent branch of median nerve Deep branch of ulnar nerve.	Flexes the proximal phalanx of thumb

2. Adductor pollicis

Transverse - longitudinal ridge on palmar surface of 3 rd metacarpal bone oblique - bases of 2 nd and 3 rd metacarpal, trapezoid capitate by crescentic origin	Ulnar side of base of proximal phalanx of thumb	Deep branch of ulnar nerve	Approximates the thumb to index finger
---	---	----------------------------	--

HYPOTHENAR

<i>Origin</i>	<i>Insertion</i>	<i>Nerve Supply</i>	<i>Action</i>
1. Palmaris brevis			
Flexor retinaculum medial border of palmar aponeurosis	Skin on ulnar side of palm	Superficial branch of ulnar nerve C ₈ , T ₁	Wrinkles the skin on ulnar side of palm of deepens the hollow of palm

2. Flexor digiti minimi

Medial side of hook of hamate + flexor retinaculum	Ulnar side or proximal phalanx of little finger	Deep branch of ulnar nerve	Flexor of proximal phalanx of little finger.
Medial side of hook of hamate + flexor retinaculum	Ulnar side of palmar surface of shaft of 5 th metacarpal bone	Deep branch of ulnar nerve	Flexes the fifth metacarpal rotating it laterally at carpometacarpal joint

LUMBRICALS

<i>Origin</i>	<i>Insertion</i>	<i>Nerve Supply</i>	<i>Action</i>
1 st and 2 nd - unipennate from radial side or profundus tendons for index and middle finger 3 rd and 4 th Bipennate & arise sides for middle, ring and little fingers	Radial side of dorsal digital expansion of medial four fingers	Median - Deep branch of ulnar nerve	Flex the digits at metacarpophalangeal & extend at interphalangeal joints

MUSCLES OF LOWER LIMB

MUSCLES OF ILIAC REGION

<i>Origin</i>	<i>Insertion</i>	<i>Nerve Supply</i>	<i>Action</i>
<i>1. Iliacus</i>			
Upper 2/3 rd of iliac fossa upto inner lip of iliac crest ligament Ala of sacrum	Into psoas tendon and to the shaft of femur for 2.5cm below and in front of lesser trochanter	Femoral nerve L ₂ ,L ₃	Flexor of hip joint

Psoas major

Anterior surface and lower border By five digitations from T ₁₂ - L ₁ Vertebral bodies and intervening discs. Tendinous arches across the concave lumbar bodies.	Lesser trochanter of femur	Ventral rami of lumbar spinal nerves L _{1,2,3}	Flexor of hip joint
---	----------------------------	---	---------------------

ANTERIOR THIGH / FEMORAL MUSCLES

<i>Origin</i>	<i>Insertion</i>	<i>Nerve Supply</i>	<i>Action</i>
<i>1. Quadriceps femoris</i>			
a) Rectus femoris - straight - anterior inferior iliac spine reflected - Groove above	Base of patella	Femoral nerve L _{2,3}	Extend the knee and flexes the hip

<p>acetabulum and fibrous capsule of hip joint b) Vastus lateralis - Intertorchanteric line, anterior and inferior borders of greater trochanter, lateral lip of gluteal tuberosity, proximal half of lateral lip of liner aspera. c) Vastus medialis - Intertochantheric line, spiral line medial lip of linea aspera proximal part of medial supracondylar line. d) Vastus intermedius - Proximal 2/3rd of anterior and lateral surface of femoral shaft and distal part of lateral intermuscular septum.</p>	<p>Patellar base and lateral border</p> <p>Medial and upper bord of patella and to tuberosity of tibia.</p> <p>Lateral patellar border lateral tibial condyle</p>	<p>Femoral nerve $L_{2,3}$</p> <p>"</p> <p>"</p>	<p>Prevents lateral displacement patella in extended knee.</p> <p>Prevents medial displacement patella in extended knee.</p> <p>Extensor of knee.</p>
--	---	--	---

MEDIAL / ADDUCTOR MUSCLES OF THIGH

<i>Origin</i>	<i>Insertion</i>	<i>Verve Supply</i>	<i>Action</i>
1. Gracilis			
Medial margin of lower half of body of pubis, ramus and adjoining ischial ramus	Upper part of medial surface of tibia	Obturator nerve L ₂ ,L ₃	Flexes the leg and rotates it medially Femoral adductor

2. Adductor brevis

Front of pubic body and inferior ramus between gracilis and obturator externus	Along a line extending from lesser trochanter to linea aspera		
--	---	--	--

MUSCLES OF GLUTEAL REGION

<i>Origin</i>	<i>Insertion</i>	<i>Verve Supply</i>	<i>Action</i>
1. Gluteus maximus			
Ilium posterior gluteal line <ul style="list-style-type: none"> ● Outer surface of dorsal segment of iliac crest ● Aponeurosis of erector spinae ● Dorsal surface of lower sacrum ● Side of coccyx ● Sacrotuberous ligament ● Gluteal 	Upper fibres into iliotibial tract Deeper into the femoral gluteal tuberosity	Inferior gluteal nerve L ₅ ,S ₁ ,S ₂	Extends the flexed thigh Flexion of hip joint Lateral rotator of hip Maintains extended position of knee joint Abductor of hip joint

aponeurosis			
-------------	--	--	--

2. Piriformis

By 3 digitations from the bone between anterior sacral foramina and area lateral to it. Heal gluteal surface Capsule of sacro iliac joint Upper surface pelvic surface of sacrotuberus ligament	Upper border of greater trochanter	Branches from C ₅ , S ₁ , S ₂	Lateral rotation of extended thigh and abduction of flexed thigh
--	------------------------------------	--	--

POSTERIOR FEMORAL MUSCLES

<i>Origin</i>	<i>Insertion</i>	<i>Verve Supply</i>	<i>Action</i>
1. Biceps femoris Long			
Inferomedially on ischial tuberosity lower part of sacrotuberocus ligament Short - lateral lip of linea aspera and upper 2/3rd of lateral supracondylar bone of femur	Head of fubula Lateral tibial condyle Tibular collateral ligament	Sciatic nerve L ₅ , S ₁ , S ₂ Long - Tibial part Short common peroneal	Flexion of knee extension of hip semiflexed - lateral rotator of tinia on femur

**MUSCLES OF LEG - ANTERIOR CRURAL
MUSCLES**

<i>Origin</i>	<i>Insertion</i>	<i>Nerve Supply</i>	<i>Action</i>
<i>Tibialis anterior</i>			
Tibial lateral condyle Proximal 2/3 rd of shaft of tibia lateral surface Anterior surface of interosseus membrane Fascia crura Intermuscular septum	Medial and inferior surface of medial cuneiform and 1 st metatarsal bone	Deep peroneal L _{4,5}	Dorsi flexor of telocrural joint Invertor of foot Maintains balance of body

Extensor digitorum longus

Lateral tibial condyle Proximal 3/4 th of medial fibular surface Fascia crura Intermuscular septum Interosseous memberane	4 slips into dorsal digital expansion opposite proximal phalanx divides into 3 slips middle to base of middle phalanx, 2 to base of distal phalanx	Deep peroneal L ₅ ,S ₁	Extend the toes dorsiflexes the foot
--	--	---	---

LATERAL LEG MUSCLES

<i>Origin</i>	<i>Insertion</i>	<i>Nerve Supply</i>	<i>Action</i>
<i>1. Peroneus longus</i>			
Upper 2/3 rd of lateral surface of	By 2 slips to lateral sides of	Superficialperoneal nerve L ₅ ,S ₁ S ₂	Dorsi flexor of telocrural joint

fibula, fascial cruris anterior and posterior crucial intermuscular septum	1st metatarsal base and adjacent cuneiform, 3 rd slip-2 nd metatarsal base		Invertor of foot Maintains balance of body
--	--	--	---

POSTERIOR CRANIAL MUSCLES - SUPERFICIAL GROUP

<i>Origin</i>	<i>Insertion</i>	<i>Verve Supply</i>	<i>Action</i>
<i>1. Gastronemius</i>			
Medial head - upper and posterior of medial condyle of femur femoral popliteal surface above medial condyle Lateral - lateral surface of lateral condyle and adjoining superocondyler line	Forms tendocalcane us and joints at middle of posterior surface of calcaneus	Tibal nerve S _{1,2}	Plantar flexion Flexion of knee Provides propelling force

2. Soleus

Posterior aspect of head and proximal quater of shaft of fibula Soleal line of tibia Midial 1/3 rd of medial border of shaft of tibia	Forms tendocalcone us and joints at middle of posterior surface of calcaneus	Tibial verve S _{1,2}	Plantar flexion Steadies the leg on the foot
--	--	----------------------------------	---

Fibrous arch between tibia and fibula			
---	--	--	--

DORSAL, MUSCLE OF FOOT

<i>Origin</i>	<i>Insertion</i>	<i>Verve Supply</i>	<i>Action</i>
<i>1.Extensor digitorum brevis</i>			
Anterior part of superolateral surface of calcaneus interosseous membrane ligament, stem of inferior extensor retinaculum	Four tendons Medial to the dorsal side of base of proximal phalanx Other joint the lateral side of tendon of extensor digitorum longus for 2,3,4 toes	Lateral branch of deep peroneal nerve S _{1,2}	Extension of phalanges

PLANTAR MUSCLES OF FOOT / SOLE**FIRST LAYER**

<i>Origin</i>	<i>Insertion</i>	<i>Verve Supply</i>	<i>Action</i>
<i>1.Abductor hallucis</i>			
Flexor retinaculum Medial process of calcaneus tuberosity Planter aponeurosis Intermuscular septum	Medial side of proximal phalanx base of hallux	Medial planter Nerve S _{2,3}	Plantar flexor lateral rotation toes

SECOND LAYER

<i>Origin</i>	<i>Insertion</i>	<i>Nerve Supply</i>	<i>Action</i>
<i>1. Flexor digitorum accessorius</i>			
Midial - Midial concave surface of calcaneus Lateral - lateral tubercle of calcaneus long plantar ligament	Lateral side of tendons of flexor digitorum longus	Lateral plantar S _{2,3}	Plantar flexion of lateral 4 toes

CRANIO FACIAL MUSCLES**EPLCRANIAL MUSCULATURE**

<i>Origin</i>	<i>Insertion</i>	<i>Nerve Supply</i>	<i>Action</i>
<i>1. Occipitofrontalis</i>			
Occipitalis - lateral 2/3 of highest nuchal line and mastoid temporal bone. Frontalis - has no bony attachments arise from front of gale aponeurotica	Medial fibres are continuous with corrugator supercilli and orbicularis oculi, lateral with orbicularis over the zygomatic process of frontal bone. All fibres join epicranial aponeurosis anterior to coronal suture	Posterior auricular branch. Temporal branch of facial nerve	Retract the scalp Frontalis raise the eyebrows and nasal skin Acting alternatively move entire scalp back and forwards

CIRCUMORBITAL AND PALEBRAL MUSCULATURE

<i>Origin</i>	<i>Insertion</i>	<i>Verve Supply</i>	<i>Action</i>
<i>1.Orbicularis Occuli orbital</i>			
Nasal part of frontal bone, frontal process of maxilla and to medial palpebral ligament. Palpebeal - medial palpebeal ligament and bone just above the ligament Lacrimal - upper part of lacrimal crest and luteal surface of lacrimal bone.	They form complete loop and upper fibres blend with frontalis and corrugator supercilli. Its fibres swap cross the eyelids anterior to orbital septum interlaxting at the lateral commissure as lateral palpebral raphe. Attached to torsi near the lacrimal conalliculi and lateral palpebral raphe	Temporal and zygomatic branches of facial nerve	Orbital Closes wywlids tightly as in protecting the eye from bright light. Closes the lids gently in sleep of rapidly in blinking. Draws the lids and lacrimal papillae and dilates the sac. When the entire muscle contracts the frontal temporal and molar skin is down towards the medial orbital angle.

BUCCOLABIAL MUSCULATURE

<i>Origin</i>	<i>Insertion</i>	<i>Verve Supply</i>	<i>Action</i>
<i>1.Mantalis</i>			
Inferior labial fenulum	Mandibles incisive fossa and mental skin.	Mandibular marginal branch of facial nerve	Raises the mental tissues mentolabial

			sulcus and base of lower lip - aid in protection / excession
--	--	--	--

2. Buccinator

Ouper surface of alveolar process of maxilla mandible opposite the molar teeth. Pterygomondibular raphe A fibrous bend extends from pterygoid hamulus to maxillary tubersity	Upper fibre straight to upper lip lower pass straight to lower lip intermediate fibres undergo chiasmatic decussation at modiolus and upper join with orbicularis oris of lower with upper lip	Lower buccal branches of facial nerve	Comperss the cheeks against teeth Forcibly expels the air between the lips from inflated vestibule
--	--	---------------------------------------	---

MUSCLES OF MASTICATION

<i>Origin</i>	<i>Insertion</i>	<i>Verve Supply</i>	<i>Action</i>
1. Masseter			
Superficial - maxillary process of zygomatic arch. Middle - Medial side of anterior 2/3 of zygomatic arch lower border of posterior 1/3rd	To mandibular angle and lower posterior half of lfteral surface of its rami Central part of mandibular ramus	Anterior trunk of mandibular nerve	Occlusion of teeth in mastication Help in side to side movement of mandible

Deep - Deep surface of zygomatic arch	Upper part of mandibular racus and its coronoid process		
---------------------------------------	---	--	--

DEEP MUSCLES OF BACK

<i>Origin</i>	
<i>Erector spinae</i>	
Median sacral crest lumbar and eleventh and twelfth thoracic spines and superaspinous ligaments. Medial side of dorsal part of iliac lateral sacral crest	Divide in upper lumbar region lateral - Ilio cervicalis intermediate - Lonissimus Medial - spinalis

ORBITAL MUSCLES

EXTRINSIC MUSCLES OF EYEBALL

<i>Origin</i>	<i>Insertion</i>	<i>Verve Supply</i>	<i>Action</i>
<i>Superior oblique</i>			
Undersurface of lesser wing of sphenoid medial to common tendinous ring	Sclera behind the equator in posterosuperior quadrant of eye ball	Trochlear nerve	Depression, adductor, Extorsion

5. BLOOD

INTRODUCTION

Blood is a specialized connective tissue which is fluid in nature. It is a fluid tissue composed of two parts. The intracellular substance is called plasma. The Blood is red in colour due to the presence of Hemoglobin pigment. The total volume of blood in the body is about 6 Lts. Blood is slightly alkaline with a Ph of about 7.4. The specific gravity of blood is about 1.055. The total volume of blood forms about one twelfth of the weight of the body.

COMPOSITION OF BLOOD

Blood contains a fluid called plasma. In which the cellular elements of blood are suspended.

PLASMA

Plasma is a liquid portion of the blood and contains the following they are

1. Water to the extent of 91%.
2. Proteins (albumin, globules and fibrinogen 0.8%
3. Salts like glucose, sodium chloride, iron, urea, acid and cholesterol in 0.9%. Serum is obtained from Plasma after removing fibrinogen.
4. The plasma also carries gasses like oxygen and carbon dioxide.
5. The internal sections like Enzymes and Antigens.

CELLULAR ELEMENTS OF BLOOD:

The cellular elements of blood are s follows:

1. Red blood cells (erythrocytes)
2. White Blood cells (Leucocytes)
3. Platelets (Thrombocytes)

RED BLOOD CELLS

1. These Red blood cells or RBC's are also called as erythrocytes.
2. They are circular, biconcave, disc shaped cells.
3. They do not have a nucleus
4. They have a respiratory pigment called Haemoglobin.
5. The normal RBC count is 4.5 to 5 millions per cu mm.
6. There are about 5,000,000 red blood cells in each cubic millimeter.
7. R.B.C. is serve important functions such as transport of oxygen and maintenance of acid base balance.
8. They are produced in the blood bone marrow and destroyed in the spleen.
9. The average life span of RBC is 120 days.
10. They are also produced in the flat bones and long bones like sternum.
11. Roulex formation is the tendency of RBC to stick to one another like a pile of coin.
12. Polycythemia is a condition where there is an increase in the number of RBC's.
13. Erythrocyte sedimentation rate (ESR) it is the rate at which RBC's sink to the bottom. Normal values of ESR are
3 to 5 mm per hour in males
4 to 7 mm per hour in females

ERYTHROPOIESIS

It is the process by which RBC's are formed in the foetus, RBC's are formed in liver, spleen and red bone marrow. After birth, they re formed only in the red bone marrow of sternum, ribs, vertebrae etc. the stages of development of RBC's are as follows.

1. Proerythroblast

2. Normoblast
3. Reticulocyte
4. Erythrocyte.

Both vitamin B12 and folic acid are necessary for the development of RBC's .

HEMOGLOBIN

It is the respiratory pigment of erythrocytes. The red colour of blood due to hemoglobin. It contains globin a protein which is conjugates with heme. Heme molecule contains four pyrrole rings with iron in the centre. The hemoglobin content of body is about 15 G per 100 ml of blood. Anemia occurs due to a decrease in hemoglobin.

FUNCTIONS OF HEMOGLOBIN

1. Transport of oxygen and carbondioxide
2. Maintenance of acid base equilibrium
3. As a source for the formation of bilirubin.

WHITE BLOOD CELLS

1. They are colourless cells containing a nucleus. They are also called as leucocytes.
2. They are larger in size than RBC's. Also their number is less when compared to RBC's (about 8000 per cumm).

CLASSIFICATION OF WHITE BLOOD CELLS

These are classified as the following.

1. Granulocytes

These are of three types they are

1. Neutrophils
2. Eosinophils
3. Baso phils

These W.B.C's have granules in the cytoplasm. They

have a nucleus which contains two or more lobes.

NEUTROPHILS:

(Polymorphs) They contain granular cytoplasm which stains with neutral dyes. The nucleus may contain 2 to 5 lobes 65 to 75% of total W.B.C's.

EOSINOPHILS:

(Acidophils) These cells are slightly larger than neutrophils. The granules are coarse and closely packed. These granules take up acid stain.

BASOPHILS:

(Most cells) they contain coarse granules as in eosinophils. But these granules stain blue with basic dyes. The nucleus is kidney shaped or lobulated.

AGRANULOCYTES :

This type of WBC's do not have granules but they have a single nucleus which is not lobed. They are classified into further types they are.

1. Lymphocytes
2. Monocytes

Lymphocytes:

They are of two types:

a. Small lymphocytes :

They occur to the extent of 25% of total WBC's they are smaller in size with a nucleus occupying almost the whole of the cell. So the cytoplasm is less.

b. Large Lymphocyte:

They are larger in size containing more cytoplasm.

Monocytes:

They are the largest of W.B.C's they occur to the

extent of 2 to 4% of WBC's they contain an eccentric nucleus which is notched in the inner side.

FUNCTIONS OF WBC'S :

1. Protection against infection :

This is done by neutrophils and monocytes which engulf bacteria. This process is called as phagocytosis.

2. To aid in the repair of injured tissues.

3. To produce immune substances which defend against diseases. This is done by lymphocytes through the synthesis of Gammaglobulin

4. Basophils secrete an anticoagulant substance called heparin.

PLATELETS :

1. These are called as Thrombocytes.
2. These are round or oval shaped cells with biconcave surface.
3. They are roughly one fourth of size of RBC. Normal platelet count is 2 to 5 lakh per cumm of blood.
4. Platelets do not have a nucleus, but cytoplasm contains distinct granules. They are synthesized by megakaryocytes (giant cells) of bone marrow.

FUNCTIONS OF PLATELETS

1. Thromboplastin liberated from platelets is essential for clotting.
2. They close minute lesions in the wall of blood vessels.
3. They aid in body's defense mechanism against bacteria.
4. They contain histamine and serotonin
5. They contain some antigenic substance also

"Thrombocytopenia". It is a condition where there is a decrease in platelet count.

CLOTTING OF BLOOD OR COAGULATION OF BLOOD

Clotting of blood is a defense mechanism of the body. It prevents loss of blood from site of injury. If a leak develops in blood vessels. A clot is formed and it plugs the leak. This prevents the loss of blood.

MECHANISM OF CLOTTING

Clotting of blood occurs in the following stages

1. "Thromboplastin":

It is liberated from disintegrated tissues and damaged platelets.

2. "Thromboplastin" converts prothrombin into thrombin.
This occurs in presence of calcium ion.
3. Thrombin converts fibrinogen to fibrin
4. The insoluble forms threads, the formed elements of blood get entangled in this and form the clot.

CLOTTING FACTORS

The various factors involved in the scheme of clotting described above are designated by numbers as factors I, II. These factors are:

Factors I	-	Fibrinogen
Factors II	-	Prothrombin
Factors III	-	Thromboplastin
Factors IV	-	Calcium
Factors V	-	Quicks labile factor
Factors VI	-	Existence of these factors not accepted
Factors VII	-	Quicks stable factor
Factors VIII	-	Antihemophilic factor
Factors IX	-	Christmas factor

Factors V and VII are required for the conversion of damaged tissue into thromboplastin. Factor VIII is the antithrombophilic factor called as haemophilia. Factor IX is called Christmas factor. In an American Negro named Christmas, all the other factors were present. But his blood did not clot. So this factor was called as Christmas.

CLOTTING TIME

It is the time taken for the clotting of human blood removed from circulation. The average clotting time varies from 5 to 15 minutes.

BLOOD GROUPS

In early times, transfusion of blood from one person to another was dangerous and unsuccessful. This is because plasma of some individuals contains some factors. These factors produce agglutination or hemolysis of the erythrocytes of other persons. These reactions occur due to the agglutination in blood. Blood is grouped as follows:

Group A	-	has A agglutinogen and B agglutinin
Group B	-	has B agglutinogen and A agglutinin
Group AB	-	has AB agglutinogen and RD agglutinin
Group 'O'	-	has RD agglutinogen and a and agglutinin

Agglutination occurs between the same type of Agglutinogen and Agglutinin. But no Agglutination occurs between different types of Agglutinogens and agglutinin. So it can be seen that group O blood can match with all blood groups. But this individual group of individual can receive blood only from O group and not from any other group. Individuals with O group of blood are called universal donors.

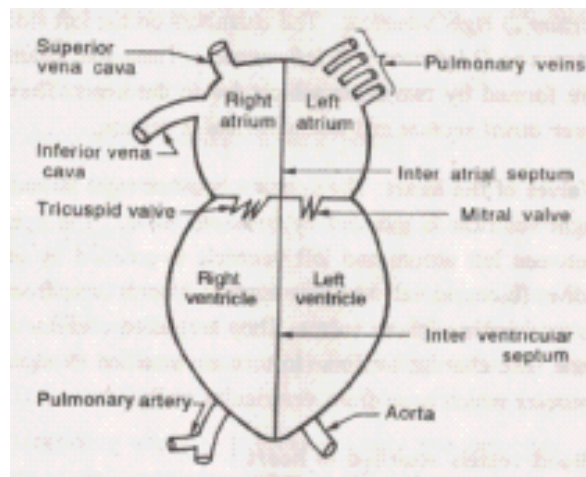
Individuals with blood group AB can receive blood from all groups. They are called as recipients.

6. CARDIOVASCULAR SYSTEM

The cardiovascular system consists of heart and blood vessels. It is mainly a transport system. It transports respiratory gases, nutrients and excretory products to various parts of the body. Blood is the medium through which these substances are transported.

HEART

Heart is a conical, hollow, musculotendinous organ. It lies in the thorax between the lungs and behind the sternum. It is about 10 cm long and weighs about 300 grams. The base of the heart is above and apex is below.



1. Position of the heart :

The heart lies in the thorax between the lungs and behind, the sternum. Two thirds of the heart is on the left side. It lies obliquely. It is directed more towards the left side than on the right side. The apex of the heart lies at the level of 5th inter costal space, 9 cm to the left of midline. The base extends to the level of second rib.

2. Structure of the heart

- i) Heart is surrounded by an outer covering called

pericardium. It contains two layers called visceral pericardium and parietal pericardium. Pericardial fluid is present between these two layers.

- ii) The middle layer is made of heart muscle fibres. It is called as myocardium.
- iii) The inner lining is called as endocardium.

3. Chambers of the heart :

Heart is made of four chambers. The two chambers on the right side are known as 1) right atrium 2) right ventricle. The chambers on the left side are known as 1) left atrium 2) left ventricle. These four chambers are formed by two septa which divide the heart. They are "inter atrial septum" and "interventricular" septum.

4. Valves of the heart :

The opening between right atrium and right ventricle is guarded by "tricuspid valve". The opening between left atrium and left ventricle is guarded by "mitral valve" (bicuspid valve.) Some tendinous cords arise from the lower border of these valves. They are called chordae tendinae. The "chordae tendinae" in turn are attached to papillary muscles which arise from ventricular walls.

5. Blood vessels attached to heart:

- i) The right atrium receives *superior vena cava* and *inferior vena cava*. They carry venous blood to heart.
- ii) From the right ventricle, arises the *pulmonary artery*. It carries venous blood to lungs for oxygenation.
- iii) The left atrium receives four *pulmonary veins*. They carry oxygenated blood to heart.

6. Nerve supply :

Heart is supplied by sympathetic and vagus nerves. Branches from these nerves pass to the sino auricular node.

ARTERIAL AND VENOUS SYSTEM:

The heart pumps blood into arteries. The arteries divide and subdivide and finally end in capillaries. The capillaries later unite to form veins. The veins return blood to the heart.

So arteries carry pure blood away from the heart. Veins carry impure blood to the heart. Capillaries are minute channels.

Histologically, arteries and veins are made of the following three layers.

- | | | |
|-----------------------------|---|---------------------|
| 1. <i>Tunica adventitia</i> | - | outer fibrous layer |
| 2. <i>Tunica media</i> | - | middle muscle layer |
| 3. <i>Tunica intima</i> | - | inner serous layer |

THE ARTERIES

Aorta is the main artery in the body. It arises from the left ventricle. The opening of aorta is guarded by semi lunar valve. Aorta consists of three parts: 1) Ascending aorta 2) Arch of aorta 3) Descending aorta.

1. Ascending aorta :

It gives off only two branches. They are a) right coronary artery b) left coronary artery. These arteries supply blood to heart itself.

2. Arch of aorta :

It supplies blood to head, neck and upper limbs. It gives off the following branches

- i) The innominate artery
- ii) Left common carotid artery
- iii) Left subclavian artery

3. Descending aorta : It is further classified into:

i) Thoracic aorta which is the part above the diaphragm. It supplies blood to the wall of chest cavity and its viscera.

ii) Abdominal aorta which is the part below the diaphragm. It supplies body wall of abdominal cavity and its viscera.

Branches of ascending aorta : They are the right and left coronary arteries.

1. The right coronary artery runs in a groove between the right atrium and right ventricle.
2. The left coronary artery runs in a groove between the left atrium and left ventricle. These two arteries give off branches which supply the heart muscle.

Branches of Arch of aorta

1. The inominate artery (brachiocephalic artery):

It divides into:

- i) Right common carotid artery which further divides into:
 - a) Internal carotid artery
 - b) External carotid artery
- ii) Right subclavian artery

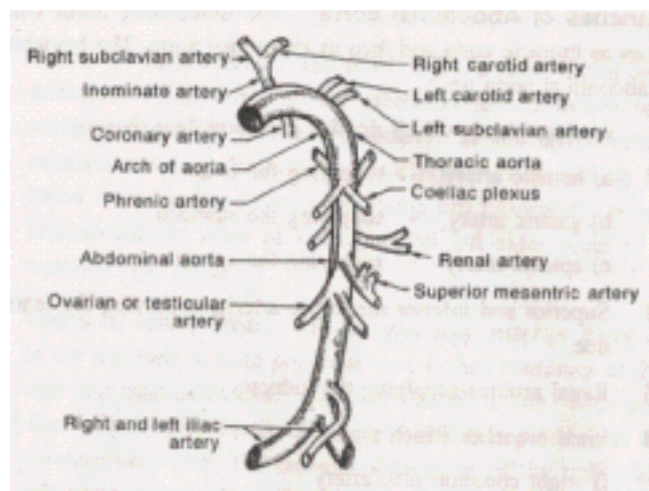
2. Left common carotid artery which also divides into:

- a) internal carotid artery
- b) external carotid artery.

3. Left subclavian artery

Branches of internal carotid artery are:

- i) Anterior cerebral artery - supplying the brain
- ii) Middle cerebral artery - supplying the brain
- iii) Ophthalmic artery - supplying the eye



The cerebral arteries unite with basilar artery (branch of vertebral artery) and form the "circle of Willis".

Branches of external "carotid artery" are:

- i) Facial artery - supplying the face
- ii) Maxillary artery - supplying the jaws
- iii) Temporal artery supplying temporal parts of skull
- iv) Occipital artery - supplying occipital parts of skull

Courses and branches of right and left subclavian arteries:

The subclavian artery enters into the axilla and continues as "axillary artery". At the lower boundary of axilla, it becomes brachial artery. Then it runs down the arm and divides into 1) "radial artery" 2) "ulnar artery". These two arteries unite in the palm and form the "palmar arch". This arch gives rise to digital arteries which supply the fingers.

Branches of Abdominal aorta :

The descending aorta continues as thoracic aorta and then as abdominal aorta. The branches of abdominal aorta are:

- 1 Coeliac plexus which divides into three branches:
 - a) hepatic artery - supplying the liver
 - b) gastric artery - supplying the stomach
 - c) splenic artery - supplying the spleen
2. Superior and inferior mesenteric arteries-supplying the intestine
- 3 Renal arteries-supplying the kidney.
4. Final branches which are:
 - i) right common iliac artery .
 - ii) left common iliac artery

These common iliac arteries divide into

- i) internal iliac artery
- ii) external iliac artery

Internal Iliac Artery:

It supplies the pelvic organs. In the female, it gives off a branch called "uterine artery" which supplies the uterus.

External iliac artery:

it continues in the thigh as femoral artery. In the

popliteal fossa it continues as "popliteal artery". This divides in the leg into:

- i) Anterior tibial artery which gives rise to dorsalis pedis artery.
- ii) Posterior tibial artery which gives rise to plantar artery.

The dorsalis pedis artery and plantar artery unite to form "plantar arch". This arch gives rise to digital branches supplying the toes.

THE VEINS

Veins of upper limb :

The veins of fore arm are "radial vein" and "ulnar vein". They unite at the elbow to form "brachial vein". It continues as "axillary vein" and finally as "subclavian vein". The subclavian vein joins with "internal jugular vein" (which brings blood from head and neck) and forms brachiocephalic vein. The brachiocephalic veins of the right and left sides unite to form a "superior vena cava".

Veins of lower limb :

The anterior and "posterior tibial veins" of the leg unite to form popliteal vein. It then continues as "femoral" vein and then as "external iliac vein". Later, it joins with internal iliac vein (which drains the blood from pelvic organs) and forms common iliac vein. The "common iliac veins" of the right and left side to form the "inferior vena cava".

Veins of head and neck :

The venous blood from head and neck is drained through internal jugular vein and external jugular vein. These two veins join with the subclavian vein to form brachiocephalic vein. The brachiocephalic veins of the right and left side open into the inferior vena cava.

Venous sinuses :

These sinuses lie between the two layers of dura matter. They receive blood from brain and interior of the skull. This venous blood is drained into internal jugular vein. These sinuses are:

1. *Superior sagittal sinus*: It lies in the upper edge of falx cerebri. It runs in the median plane from the frontal to occipital region.
2. *Inferior sagittal sinus*: It runs in the lower edge of falx cerebri.
3. *Straight sinus*: It runs between falx cerebri and tentorium cerebelli..
4. *Transverse sinuses*: They are two in number and lie close to the skull. They receive blood from other sinuses, intestine and pancreas) to liver.
5. *Cavernous sinuses*: They are two in number. They lie one on each side of the sphenoid bone. They drain blood from orbit, nose and cheek.

BLOOD CIRCULATION :

Depending on the course of blood, circulation can be classified into:

1. Systemic circulation
2. Pulmonary circulation
3. Coronary circulation
4. Portal circulation

1. Systemic circulation :

It is the circulation involving blood. Supply to all parts of the body except lungs. This circulation starts from aorta (which carries oxygenated blood from left ventricle). It breaks up into smaller arteries and finally ends in capillaries. The capillaries unite to form venules which join up ultimately to form large venous trunks namely superior vena cava and inferior vena cava. These two venous trunks open in the right atrium of heart.

2. Pulmonary circulation :

It is the part of circulation involving the purification of blood in lungs. Impure venous blood is pumped by the right ventricle. The pulmonary artery carries this blood to lungs where it is oxygenated (purified). Four pulmonary veins carry this purified blood from lungs. These veins open in the left atrium.

3. Coronary circulation :

The circulation involves blood supply to the heart itself. The right and left coronary arteries arise from ascending aorta. They supply blood to the heart. The venous blood is collected by

the coronary sinus which opens in the right atrium.

4. Portal circulation :

It is the circulation of blood through the liver. In this circulation :

- i) "Portal vein" carries blood (that has circulated in stomach, intestine and pancreas.
- ii) The portal vein divides into capillaries. These capillaries join with the capillaries of hepatic vein.
- iii) The venous blood of liver is collected by hepatic vein which joins with inferior vena cava.

FUNCTIONS OF THE HEART :

The heart acts as a pump. It maintains a constant circulation of blood throughout the body. It is achieved as follows

1. The superior vena cava and the inferior vena cava bring venous blood from various parts of the body to the heart. This venous blood fills the atrium.
2. When it is full, the right atrium contracts sending blood to the right ventricle.
3. Now the right ventricle contracts. This sends blood to the lungs through the pulmonary trunk (which divides into right and left pulmonary arteries)
4. The blood gets oxygenated in the lungs. The oxygenated blood is carried by pulmonary veins to the left atrium.
5. Now, the left atrium contracts and sends blood to the left ventricle.
6. Now, the left ventricle contracts and sends blood into aorta. This blood is circulated throughout the body.

CARDIAC CYCLE :

The function of the heart is to maintain a constant circulation of blood throughout the body. This is achieved by rhythmic contraction of its muscle.

Cardiac cycle is the sequence of events which occur in the heart during a single beat. The rate of heart is 72 beats per minute. So the time taken for one beat is 0.8 second. So the sequence of events occur every 0.8 second. Cardiac cycle occurs in two phases. They are

1. Systole - a period of contraction
2. Diastole - a period of relaxation

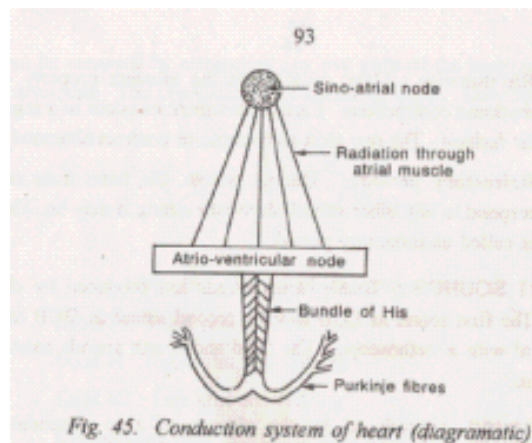
The cycle of events occurs as follows

1. To start with, blood from the veins fill the two atria, i.e., / the superior and inferior vena cava fill the right atrium; the pulmonary veins fill the left atrium.
2. This is followed by a wave of contraction in the atria. This leads to emptying of atrial blood into the respective ventricle.
3. When the ventricles are full, they contract. Now, the blood present in ventricles is forced into systemic and pulmonary circulation. At this stage, the semilunar valves guarding the aorta and pulmonary arteries are opened. At the same time, the atrioventricular valves are closed. This period of muscular contraction of the heart is called "systole".
4. This is followed by a period of rest called "diastole". During this period, there is no muscular contraction. This sequence of events constitute the cardiac cycle.

CONDUCTING SYSTEM OF THE HEART :

The impulses for cardiac contraction are transmitted through the conduction system of the heart. This system is made of 1) Sino atrial node 2) Atrio ventricular node 3) Bundle of His 4) Purkinje fibres. The conduction of impulses occurs in the following sequences

1. The impulses for cardiac contraction start at "sinoatrial node" (SA node). It is present at the opening of superior vena cava into the right atrium. SA node is called as pace maker of heart.
2. The impulses then pass through the atrial muscle.
3. Later, the impulses pass to "atrio-ventricular node" (AV node). It lies in the upper part of atrio-ventricular septum.
4. From here, the impulses pass to "bundle of His". It is a special bundle of nerve and muscle tissue. Also, it is the only muscular connection between the atria and ventricles.
5. The bundle of his passes through the interventricular septum. Later it divides into branches called purkinje fibers. The right and left branches of this fiber supply the two ventricles.



This specialized conduction system of heart provides greater conductivity of cardiac impulses.

PROPERTIES OF CARDIAC MUSCLE :

The cardiac muscle has certain characteristics. They are:

1. Contractility:

By contraction of the cardiac muscles the heart pumps the blood out of its chambers.

2. Conductivity:

The impulses for cardiac contraction are conveyed through a specialised conduction system.

3. Rhythmicity:

Heart muscle has the inherent property of rhythmic contraction. Cardiac contraction occurs in a regular fashion. The two atria and ventricles contract alternately.

4. Refractory period :

During systole, the heart does not respond to any other stimuli, however strong it may be. This is called as refractory period.

HEART SOUNDS :

Totally four sounds are produced by the heart. The first sound as LUB and the second sound as DUB can be heard with a stethoscope. The third and fourth sounds cannot be heard.

First sound is produced by the closure of atrioventricular valves. This is loud and of a long duration.

Second sound is produced by the closure of semi lunar valves ('aortic and pulmonary). It is shrill and of a short duration.

PULSE:

Pulse is the throbbing sensation felt over the walls of arteries. It is defined as the pressure difference transmitted in the form of a wave over the arterial walls. Pulse rate is almost the same as heart rate (60 to 80 per minute). The wrist is the common site where pulse is usually felt. At this site, the radial artery is very superficial. This pulse is called as *radial pulse*. Other arteries where pulse can be felt are carotid artery, facial artery and temporal artery. In case of fever, the rate of pulse increases at the rate of 10 per every rise of 1°F.

Generally veins do not exhibit pulsation. The only vein which exhibits pulsation is jugular vein (which is nearer to heart).

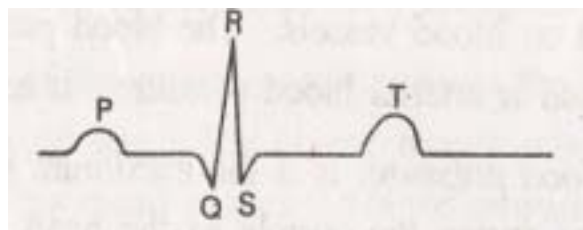
ELECTROCARDIOGRAM (ECG) :

It is the recording of electrical activity of the heart. Electrocardiograph is the instrument which is used to record the electrical current generated in the heart. By means of this instrument, the electrical current generated in the heart is conducted to remote parts of the body. The heart current can be recorded by connecting any two parts of the body with this instrument. The connections are called as leads. They are

Lead I Right arm and left arm.

Lead II: Right arm and left leg.

Lead III Left arm and left leg.



Connections Over the chest with indifferent electrodes are also sometimes used. The ECG recordings are designed by letters P, Q, R, S, and T.

The wave P is caused by contraction of atria.

The wave Q, R and S are produced by the contraction of ventricles.

The wave T is produced by the relaxation of ventricles.

During diseases of the heart, these waves are abnormal in shape and position.

CARDIAC OUTPUT :

It is defined as the quantity of blood pumped by the heart in one minute.

Stroke volume is the amount of blood ejected per beat of the heart. It is about 70ml. So, every minute some 5040 ml (nearly 5 liters) of blood is pumped by the heart.

Cardiac output depends on the following factors

1. Amount of blood returned to the heart through veins (venous return).
2. Force and rate of contraction of the heart.
3. Peripheral resistance offered by blood vessels.

BLOOD PRESSURE (BP) :

It is defined as the lateral pressure exerted by blood on blood vessels. The blood pressure which is normally expressed is arterial blood pressure. It has two phases:

1. Systolic blood pressure:

It is the maximum blood pressure, This occurs during the systole of the heart. (range 100 to 120 mm Hg.)

2. Diastolic blood pressure: It is the minimum pressure. It occurs during the diastole of the heart (range 60 to 80 mm Hg.)

Pulse pressure is the difference between systolic and diastolic blood pressure (It is nearly 40 mm Hg.)

Factors affecting blood pressure:

1. Blood volume
2. Cardiac output
3. Peripheral resistance
4. Elasticity of blood vessels

5. Diameter of the lumen of blood vessels
6. Viscosity of blood

1. **Blood volume** is the total amount of blood in circulation. A sufficient amount of blood in blood vessels is necessary to maintain normal blood pressure. Loss of blood as in hemorrhage produces a fall in blood pressure.

2. **Cardiac output** is the quantity of blood pumped by the heart in one minute. It is the product of stroke volume (the amount of blood ejected per beat of the heart) and rate of the heart. An increase in stroke volume increases systolic blood pressure. An increase in cardiac output increases both systolic and diastolic blood pressure.

3. **Peripheral resistance** is the resistance offered by blood vessels for the flow of blood. Resistance is offered mainly by small blood vessels, especially arterioles.

4. **Elasticity** of the arterial walls distends the aorta when the ventricle contracts. The elastic recoils when the ventricle relaxes. This recoil pushes the blood downwards. Decrease in elasticity as in atheroma produces a rise in blood pressure.

5. **Diameter of the lumen of blood vessels** can be altered. Narrowing of the lumen increases the resistance to blood flow and this increases blood pressure. Enlargement of the lumen has the opposite effect.

6. **Viscosity of blood** is its stickiness. The viscosity of blood depends on plasma, plasma proteins and number of the red blood cells. An increase in viscosity increases blood pressure.

Measurement of blood pressure:

Blood pressure is usually measured by an instrument called "sphygmomanometer". It consists of a mercury manometer, cuff and hand pump. The cuff is tied around the cubital fossa of the individual. Then the hand pump is pressed so that air is inflated in the cuff. When the cuff is fully inflated, air pressure is more than

blood pressure. So blood flow in the brachial artery is completely obstructed. Now the hand pump is slowly released, till the time the appearance of the first sound is heard (by means of a stethoscope put in the cubital fossa). The manometric reading is now noted. This reading is the systolic blood pressure.

Later, the hand pump is slowly released till the time the sound becomes louder and louder. Later it stops. The manometric reading is noted when the sound disappears. This reading is the diastolic blood pressure.

CARDIOVASCULAR DISORDERS DISORDERS OF HEART

Cardiac failure :

It is a condition in which the myocardium of ventricle is unable to maintain sufficient circulation of blood to meet the needs of the, body. Depending on onset it may be classified as: 1. *Acute cardiac failure*: When the onset is sudden.

2. *Chronic cardiac failure*: When the onset is gradual.

Stenosis of valves: It is the narrowing of the valves of the heart. In this condition, the edges of the cusps (of the valves) become rough. So they stick together and narrow the valvular opening..

Incompetence of valves:

It is a functional defect caused by the failure of the valve to close completely. This allows blood to flow back into the ventricle when it relaxes.

Ischemic heart disease:

It occurs due to narrowing or occlusion of one or more branches of coronary arteries. It may lead to angina pectoris.

Angina pectoris (angina of effort):

It is pain occurring due to myocardial ischemia. It occurs due to narrowing of coronary arteries. Because of this, physical effort causes severe ischemic pain.

Myocardial infarction:

It is the death of an area of cardiac tissue due to lack of coronary blood supply to that segment of the myocardium. It occurs due to occlusion of coronary artery.

Cardiac arrhythmia: It is a disorder in cardiac rate and rhythm. It occurs due to defective impulse formation and defective impulse conduction in the heart.

DISORDERS OF BLOOD VESSELS**ARTERIES****Arteriosclerosis :**

It is thickening and inelasticity of arteries

Atherosclerosis :

It is thickening of arterial walls due to the deposition of fat (intimal fibrofatty plaques).

Aneurysm :

It is local abnormal dilate of an artery. It is classified into three types: fusiform, saccular and dissecting.

Embolus :

It is clot moving in circulation and becomes impacted in a blood vessel.

Thrombus :

It is a obstructing a blood vessel at the point where it is actually formed.

VEINS**Phlebitis :**

It is infection of the vein wall due to inflammation or injury.

Thrombophlebitis

It is inflammation of vein complication by an obstructing clot.

Varicose vein :

It is a dilated and tortuous superficial vein. This occurs because valves in the veins is not close. So the backward flow of

blood in the veins is not prevented. This leads to dropping back of the column of the blood in the veins. Varicose vein commonly occurs in 1. long saphanous vein 2. short saphanous vein 3. anterior tibial vein.

DISORDERS OF BLOOD PRESSURE

Hypertension :

It is a rise in blood pressure above normal. It is difficult to define the average normal blood pressure. It varies from one age group to other. The blood pressure in an adult may be 120/80. At the age of 45 it may be 150/90. At the age of 60 it may be 160/100. A range of 40 to 50 normally exists between systolic and diastolic blood pressure. A diastolic pressure of over 130 mm Hg is a very serious degree of hypertension.

Hypertension produces lot of complications like: 1) changes in arteries e.g. cerebral hemorrhage 2) changes in eyes e.g. retinal hemorrhage 3) changes in kidney affecting renal function.

Hypotension :

It is low blood pressure which can be physiological in health e.g. during rest and in elderly people. Mostly it occurs as a complication of other diseases e.g. shock, myocardial infarction and hemorrhage. Low blood pressure leads to inadequate blood supply to brain. It may produce brief unconsciousness (fainting). If this is prolonged death may result.

LYMPHATIC SYSTEM

Lymph is a tissue fluid which is formed by the passage of substances from blood capillaries into tissue spaces. It flows in a closed system called lymphatic system. This system consists of lymph vessels, lymph capillaries, lymph nodes etc.

Composition of lymph :

Lymph is a colourless fluid which consists of blood plasma and lymphocytes but not platelets. It is alkaline in reaction. Compared to plasma, it contains a high amount of fat. It contains low proteins and nutrients. Lymph from intestine contains a high amount of fat

Functions of lymphatic system:

1. Lymph nodes protect the body against infection by filtering and destroying bacteria.
2. Also, lymph nodes are the sites where lymphocytes are produced.
3. The lymphatics drain the excess fluid from tissues back to circulation.
4. The lymphatics carry waste products from tissues to blood.

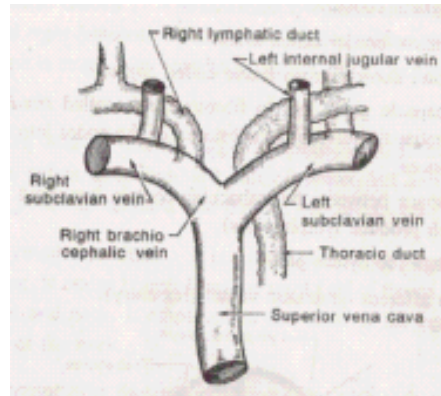
Formation of lymph:

Lymph is formed by filtration of tissue fluid into lymphatic capillaries.

Lymphatic system :

It is a closed system through which lymph flows. This system consists of "lymph capillaries", lymph vessels, lymph nodes etc

1. The lymphatic system initially starts with "lymphatic capillaries". They are thin walled capillaries similar to blood capillaries. These capillaries are composed of a single layer of cells.
2. From the lymphatic capillaries, lymph flows into collecting trunks.
3. The collecting trunks end up in lymphatic vessels. In the course of these vessels, there are some lymph nodes.



4. The lymphatic vessels unite to form larger trunks. These trunks open into right lymphatic duct and thoracic duct.
5. These ducts open into subclavian vein.
6. Villi of the small intestine contain small lymphatic vessels called "lacteals". The digested fat is absorbed through these lacteals. The lymph that flows through these vessels is called chyle. Chyle contains a high amount of fat.

Lymph nodes :

These are small, oval or bean shaped glands present in the course of lymphatic vessels. The lymph nodes are usually distributed in groups. The main groups of glands are present in the neck, axilla, thorax, abdomen and groin.

The lymph gland contains:

1. A concave border called *hylum*
2. An outer dense fibrous tissue called *capsule*.
3. The capsule gives rise to fibrous bands called trabaculae. The trabaculae divide the substance of the nodes into irregular spaces.
4. The space between the trabaculae contain lymphoid tissues (which produce lymphocytes).
5. Through the hylum pass:
 - i) an afferent lymphatic vessel (for entry).
 - ii) an efferent lymphatic vessel (for exit).
 - iii) arteries and veins.

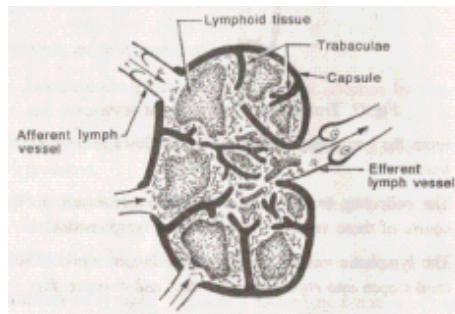
Functions of lymph nodes

1. They filter out solid particles including bacteria.

2. They produce lymphocytes.
3. Production of plasma proteins like globulin. (This is done by dissolution and disintegration of lymphocytes).

Lymphatic ducts:

The two main lymphatic ducts are thoracic duct and right lymphatic duct. After filtration by the lymph nodes, the lymph



is emptied by lymphatic vessels into these two lymphatic ducts.

Thoracic duct:

It is the larger lymphatic duct. It drains lymph from the pelvis, abdomen, left half of thorax, left arm, head and neck. It pours its contents into the left subclavian vein.

Right lymphatic duct:

It is a small dilated lymph vessel about 1 cm long. It drains lymph from the right half of thorax, right arm and head and neck. It empties into the veins at the right side of the root of the neck.

Other lymphatic tissues:

In addition to lymph node, lymphatic tissues are present in the following sites:

1. Spleen
2. Thymus
3. Tonsils
4. Appendix
5. Peyer's patches in intestine

SPLEEN :

It is a dark purple colored lymphoid structure. It is highly vascular and bean shaped and measures about 12 cm in length. It is present in the left side of the abdominal cavity below the diaphragm.

Structure of spleen: Spleen contains the following structures:

1. An outer covering of fibroelastic tissue called *capsule*.
2. Trabaculae arise from the capsule and pass into the substance of the gland.
3. The spaces between trabaculae contain the splenic tissue. These tissues contain the lymphoid tissues called as Malphigian corpuscles.
4. Spleen is supplied by splenic artery and drained by splenic vein.

Functions of spleen

1. Spleen produces all types of blood cells during foetal life.
2. Red blood cells are destroyed in spleen.
3. Histocytes of spleen ingest and destroyed foreign particles including bacteria.
4. Spleen serves as a reservoir of blood.
5. It also produces antibodies.

THYMUS :

The thymus gland contains lymphoid tissue. It lies in the thorax behind the sternum but in front of heart and arch of aorta. It weighs about 10 to 15 grams at birth and it grows until puberty. Later it gradually decreases in size and shrinks. The thymus takes part in the production of T-lymphocytes.

TONSILS:

Tonsils are collections of lymphoid tissue. There are two tonsils, one each lies on each side of the pharynx between the pillars of fauces. Tonsils are supplied with blood and lymphatic vessels. The surface of tonsil is covered with mucous membrane which is studded with crypts. Lymphocytes are present in the fluid on the surface of tonsil and also in the crypts.

- ii) Oropharynx which is continuous in front with mouth and below with laryngeal part of pharynx. Its lateral wall contains the tonsils.
- iii) *Laryngopharynx* which is the lowest part. It lies behind the larynx.

THE CEREBROSPINAL NERVOUS SYSTEM

The Nervous System is divided for description into two main parts : (1) the Central or Cerebrospinal system and (2) the Autonomic, which includes the Sympathetic and Parasympathetic Nervous System. (See Chapter 23.)

The Cerebrospinal Nervous System. This consists of the brain and spinal cord and the nerves given off from these, the peripheral nerves. Nervous tissue forms one of the four groups of the elementary tissues of the body.

Neve cells massed together form what is called the grey and in the inner part of the spinal cord.

Nerve fibres or axons form the white matter. This difference in colour is due to the axons form the conducting fibres being covered by a sheath of fatty matter, which serves to protect, nourish, and insulate the nerve fibres from each other (see Fig. 22/2).

A nerye cell with its axon and other processes constitutes a neurone. In the formation of a nerve trunk the nerve fibres are arranged in bundles called fasciculi.

A nerve fibres possesses the power of conductivity and excitability. It is capable of receiving and responding to stimuli from some outside agent for example, the stimulus may be mechanical, electrical, chemical, or psychical; this gives rise to an impulse which is conducted along the nerve fibres. A nerve impules is always conducted along a dendron to a cell, and from cell to axon.



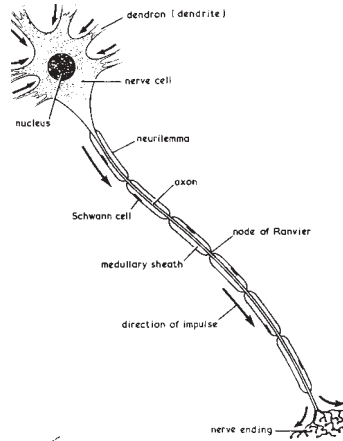
FIG. 22/1.—SECTION OF A NERVE TRUNK SHOWING SEVERAL FASCICULI SURROUNDED BY PERINEURIUM AND HELD TOGETHER BY EPINEURIUM. THE AREAS STAINED BLACK ARE FAT CELLS

328. The cerebrospinal nervous system

This is the law of forward conduction. An impulse may be passed

along a series of neurones in this way.

A motor impulse generated in one of pyramidal cells of the motor area of the cortex travel along the axon or nerve



22/2 ().

THE CEREBROSPINAL NERVOUS SYSTEM

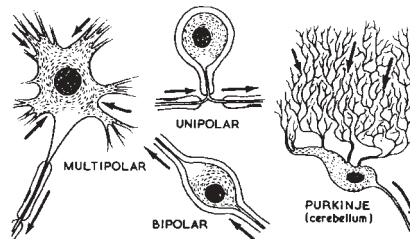


FIG. 22/3 - EXAMPLES OF NERVE CELLS. ARROWS INDICATE THE DIRECTION IN WHICH THE NERVE IMPULSE ALWAYS TRAVELS - FROM DENDRON TO CELL AND FROM CELL TO AXON.

fibre, which, passing down the spinal cord, lies in the white matter; the axon arborizes with the dendrites of motor nerve cells in the anterior horn of the spinal cord. The impulse then passes to the axons of these cells, which form the motor fibres of the anterior root of a spinal nerve, and is conveyed to terminate in a muscle.

Sensory impulses received by the nerve endings in the skin, travel by nerve fibres (dendrons) to the sensory cells in the posterior root ganglion, and thence by the axons of these cells into the spinal cord and ascend to a nucleus in the medulla, thence to be relayed to the brain. (see sensory nerve pathway, page 349). Nerve fibres travelling to and from different parts of the brain are grouped together in definite tracts in the spinal cord.

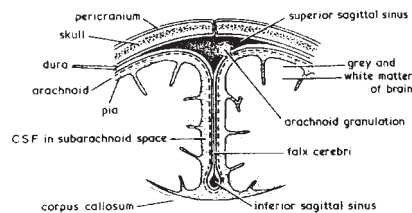
Nerve trunks formed by the cerebrospinal nerves are of three varieties :

- (1) Motor or efferent nerve carrying impulses from the brain and cord to the periphery (see motor pathway, page 348).
- (2) Sensory or afferent nerves carrying impulses from the periphery to the brain (see sensory pathway, page 349).
- (3) Mixed nerve trunks containing both motor and sensory fibres, thus carrying impulses in both directions. Most of the nerves are of this last variety.

In addition there are certain nerve fibres which link up different nerve centres in the brain and cord. These are called associated or commissural nerve fibres.

THE MENINGES

The brain and spinal cord are surrounded by the meninges, which protect the delicate nerve structure, carry the blood fluid (see page 331) minimize any blow or concussion. The meninges are in three layers.



. 22/4.

The pia mater dips into the fissures of the brain and cord and by this close contact supplies these structures with blood.

The arachnoid is a fine membrane separating the pia mater from the dura mater.

The dura mater is dense and tough; it consists of two layers; one outer layer lines the skull, an inner layer is united with it, except where the venous sinuses are formed and where the dura mater forms the following partitions :- The falx cerebri lies between the two cerebral hemispheres; its upper border forms the superior longitudinal or sagittal sinus receiving venous blood from the brain and its lower margin, the inferior longitudinal or inferior sagittal sinus, drains the falx cerebri.

The tentorium cerebelli separates the cerebellum from the cerebrum. (Reference to Fig. 11/12, page 190 indicates the positions of these sinuses and the partitions of the dura mater).

The *diaphragma sellae*, a ring-shaped fold of dura mater, covers the sella turcica, a depression on the sphenoid bone, containing the hypophysis cerebri, or pituitary gland.

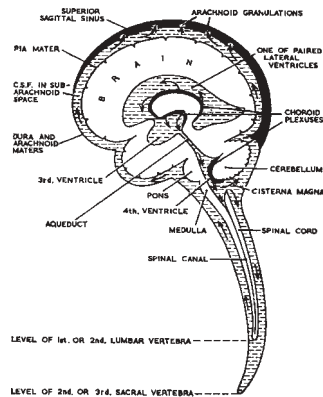
In meningitis there is inflammation of the meninges, characterized by increase in the amount and alteration of the composition of the cerebrospinal fluid (C.S.F). The infection may be bacterial or viral; diagnosis is made by examination of the cerebrospinal fluid obtained by lumbar puncture (see page 333).

The **Ventricular System** consists of several interconnected cavities within the brain into which the cerebrospinal fluid is secreted by the choroid plexuses. These choroid plexuses are composed of a network of minute capillary blood vessels and covered with pia mater which project into the ventricles and secrete cerebrospinal fluid.

The *two lateral ventricles* lie one in each cerebral hemisphere and are connected with the third ventricle which lies in the mid-line between the thalami. The third ventricle is connected by a narrow channel, the cerebral aqueduct, with the fourth ventricle which lies between the cerebellum and the pons and medulla. Openings in the roof of the fourth ventricle allow the cerebrospinal fluid to pass into the sub-arachnoid space surrounding the whole of the brain and the spinal cord.

The **cerebrospinal fluid** is a secretion produced by the choroid plexuses (see Fig. 22/5). It is a clear alkaline fluid resembling plasma. The pressure is 60 to 140 mm water.

The *circulation of cerebrospinal fluid*. The fluid is secreted by the choroid plexuses into the ventricles which lie within the brain; from opening in the fourth ventricle it passes into the central canal of the spinal cord, and from the ventricles also into the sub-arachnoid space. The fluid is now able to pass in this space over the whole surface of the brain and spinal cord until it is returned to the venous circulation by the arachnoid granulations in



22/5

the superior sagittal sinus (see Fig. 22/5).

By this arrangement the delicate nerve matter of the brain and spinal cord lies between two layers of fluid - the internal layer of fluid being contained in the ventricles of the brain, and in the central canal of the spinal cord, and the external layer of fluid in the sub-arachnoid space. By means of these two 'water beds' the central nervous system is protected.

The functions of the cerebrospinal fluid. It acts as a buffer, protecting the brain and spinal cord. It conveys nourishment to the tissues of the central nervous system.

Lumbar puncture. Because the spinal cord ends at the level of the first of second lumbar vertebrae and the sub-arachnoid space extends to the level of the second sacral vertebra, a sample of cerebrospinal fluid may be drawn off by introducing a lumbar puncture needle into the sub-arachnoid space between these points a process called lumbar puncture.

The examination of the cerebrospinal fluid thus obtained may reveal important information in conditions such as meningitis and sub-arachnoid cerebral haemorrhage.

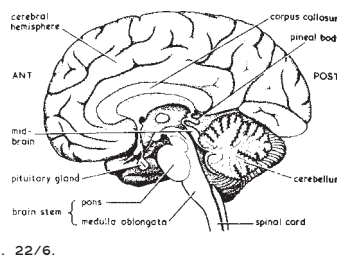
THE DIFFERENT PARTS OF THE BRAIN

Development. The brain lies within the cranial cavity of the skull. It develops from a single tube which initially shows three enlargements, the fore-runners of the brain, termed, fore-brain mid-brain and hind-brain. Thus :

The Fore-Brain, becomes the cerebral hemispheres,

	corpus straitum and the thalami	
The Mid-Brain, the mid-brain	}	These three form the Brain Stem
The Hind-Brain, the pons Varolli, medulla oblongata, and the cerebellum		

The Cerebrum fills the front and upper portion of the cranial cavity, termed respectively the anterior and middle cranial fossa (see Fig. 3/1, page 64). It consists of two large hemispheres of nerve cells (grey matter) and nerve fibres (white matter). The outer layer of grey matter is termed the cortex (see page 335). The two cerebral hemispheres are separated by a deep cleft, but united at their bases by the corpus callosum, a mass of white matter consisting of nerve fibres. Beneath this are islands of grey matter, the basal ganglia .



Areas of the Brain. Fissures and sulci divide the cerebral hemisphere into areas. The cerebral cortex is arranged in convolution or irregular folds in order to increase the expanse of grey matter. The depressions between the convolutions are called sulci and the deepest sulci form the longitudinal and lateral fissures. These fissures or sulci divide the brain into named areas or 'lobes' which correspond in position to the bones beneath which they lie, e.g. the frontal, temporal parietal and occipital lobes.

The longitudinal fissure is a deep cleft in the medial plane separating the cerebrum into right and left cerebral hemispheres; into it dips a thin plate of dura mater called the falx cerebri. Similarly a thin partition of dura mater, the falx cerebelli, divides the cerebellum into right and left hemispheres.

The lateral sulcus, or the fissure of Sylvius, separates the temporal lobe from the frontal lobe (anteriorly) and from the parietal lobe more posteriorly (see Fig. 22/7, below).

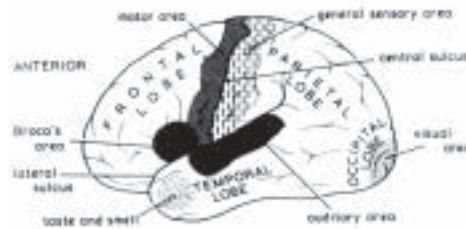


FIG. 22/7 THE LATERAL ASPECT OF THE LEFT CEREBRAL HEMISPHERE, THE CENTRAL SULCUS OR FISSURE OF ROLANDO SEPARATES THE SENSORY AND MOTOR AREAS

The *central sulcus* or fissure of Rolando separates the frontal from the parietal lobes. The occipital lobes of the cerebrum are situated behind the parietal lobes and rest upon the tentorium cerebelli - a fold of a dura mater which separates the middle cranial fossa from the posterior cranial fossa below.

The **Cerebral Cortex** is composed of many layers of nerve cells; it is the grey matter of the cerebrum. It is arranged in irregular folds or convolutions, an arrangement which increases the surface area of the cerebral cortex, as scalloping a piece of material increases the length of its exact edge.

The *white matter* lies more deeply and consists of the nerve fibres belonging to the cells of the cortex.

The *motor area* lies just in front of the central sulcus (see Fig. 22/7), extending down as far as the lateral sulcus. This area of the cortex contains large cells which form the beginning of the motor pathway which controls movement of the opposite side of the body. The body is represented upside down the lower limb, trunk, upper limb, neck and finally head controlling areas lie, from above down, in the motor area as indicated in Fig. 22/8.

The lowest part of the motor cortex is called Broca's area and is concerned with speech. Broca's area and is concerned with speech. Broca's area lies in the left cerebral hemisphere in right-handed people, and on the opposite side in those who are left-handed.

The *sensory cortex* lies immediately behind the central sulcus. Here the various modalities of sensation (see Figs. 22/7 and 22/8) are appreciated and interpreted.

The *auditory area* lies in the temporal lobe just below the longitudinal fissure. Here sound impressions are received and interpreted.

The *visual area* lies at the tip of the occipital lobe and receives

images and impressin for interpretation.

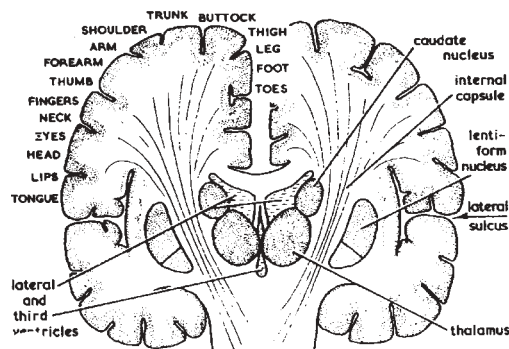
The centres of taste and smell lie well forward in the temporal lobe.

The *white matter* of the cerebral hemipheres consists of nerve fibres running to and from the cortex linking up the various 'centres' of the brain with the spinal cord.

Basal Ganglia. As already mentioned, embedded in the mass of white matter of each cerebral hemisphere are certain small areas of grey matter, termed the basal ganglia or nuclei. Two of these are the caudate and lentiform nuclei and together form the corpus striatum. These structures are closely related to another mass of grey matter, the thalamus, which lies medially to them. It is likely that this system in some way influences tone and posture, integrates and co-ordinates the main voluntary muscle movements which are the concern of the great descending motor pathway, or the pyramidal system.

The *Thalamus* is chiefly concerned with the reception of sensory impulses, which may be either interpreted at a subcortical level, or relayed on to the sensory area of the cerebral cortex. It appears to have an important

THE DIFFERENT PARTS OF THE BRAIN



22/8 - CORONAL SECTION OF BRAIN, MOTOR AREAS LABELLED ON THE LEFT, BASAL NUCLEI ON THE RIGHT.

regulating action on many of the highest centres for sensation and movement.

The *Hypothalamus*. In the region of the floor of the third ventricle are certain nuclei which have definite physiological activity. Some of them are related to the autonomic nervous system forming the 'highest part of that system'. Some nuclei also have connexions with the posterior

lobe of the pituitary gland of the endocrine system on which they exert control. Functions such as body temperature regulations, hunger and thirst are regulated by centres in the hypothalamus.

Disorder in these areas leads to tremor at rest and rigidity of movement. **Parkinsons' disease or paralysis agitans**, a progressive condition beginning in middle life, is a classical example. The head is flaxed and held stiffly, the body bent, arms at the sides with fingers flexed, the thumb approximating the fingers in rhythmical pill-rolling movements. The thighs are slightly flexed and adducted; the patient takes little mincing steps. The skin of the face is smooth and unwrinkled giving a mask-like expression. Speech is slow and monotonous.

Surgery directed to the basal ganglia produces improvement in selected cases.

The Internal capsule is formed by fibres of the great motor and sensory pathways which link the cerebral cortex with the brain stem and spinal cord. In this part of their course these nerve fibres are closely packed together as they pass between the islands of grey matter.

Thrombosis of the artery supplying the internal capsule may lead to damage of the opposite side of the body (hemiplegia); such a cerebrovascular catastrophe constitutes a 'stroke'. (See Clinical Note, Page 353).

The Functions of the Cerebrum. These have been mentioned as the various parts have been described. To summarize. The cerebral cortex contains the higher centres controlling mental behaviour, thought, consciousness, moral sense, will, intellect, speech, language, and the special senses.

The cortex is the origin of all voluntary motor impulses controlling the skeletal muscles.

It is the final area for the reception of all incoming sensory nerve impulses and for their appreciation and interpretation, including skin sensation, touch, pain, pressure, temperature, vibration, texture, shape, and size, and muscle and joint sense.

The Brain Stem is composed of the mid-brain, pons varolii and medulla oblongata.

The mid-brain forms the upper part of the brain stem. Through

it runs the cerebral aqueduct connecting the third and fourth ventricles (see. Fig. 22/5, page 332). The mid-brain may be considered in two levels:

- (1) The roof contains important reflex centres for sight and hearing.
- (2) Through the base of the mid-brain the great motor pathway descends from the internal capsule above, to continue through the pons and medulla on its way to the spinal cord.

The ascending sensory pathways, on their journey from the spinal cord, medulla and pons, pass through this portion of the mid-brain before

THE DIFFERENT PARTS OF THE BRAIN

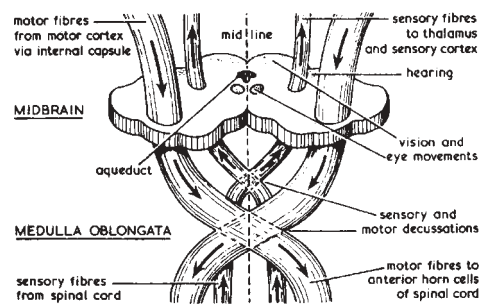


FIG. 22/9. - A SECTION OF THE MID-BRAIN SHOWING MAIN TRACTS OF FIBRES

entering the thalamus or internal capsule, to reach their final distribution in the sensory cortex of the cerebral hemispheres.

The mid-brain contains centres for the control of balance and the movements of the eyes.

The *pons Varolii* forms the middle portion of the brain stem and thus contains the same ascending and descending pathways as the mid-brain. There are many fibres running transversely through the pons which link the two lobes of the cerebellum; and the cerebellum with the cerebral cortex.

The medulla oblongata forms the lower portion of the brain stem linking the pons with the spinal cord. The medulla lies in the posterior cranial fossa and joins the spinal cord just below the foramen magnum of the occipital bone.

The main features of the medulla are that here the descending motor pathways cross from one side of the brain stem to the other. This is called

the motor discussion. A similar arrangement of the sensory pathways occurs in the medulla and is referred to as the sensory decussation.

The medulla contains the nuclei or cell bodies of several important cranial nerves. It also contains certain 'vital centres' which control respiration and the cardiovascular system. Injury to this part of the brain stem is therefore liable to have very serious consequences.

The Cerebellum is the largest part of the hind-brain. It occupies the posterior cranial fossa and is roofed over by the tentorium cerebelli, a fold of dura mater which separates it from the occipital lobes of the cerebrum.

The cerebellum is separated from the pons and medulla by the cavity of the fourth ventricle. It is divided into two hemispheres, right and left, by a deep cleft into which dips another fold of dura mater, the falx cerebelli.

The arrangement of grey and white matter is similar to that found in the cerebrum with the grey matter arranged at the surface. The surface is ridged rather than folded into convolutions, the fissures between the ridges being very much closer together than the sulci of the cerebral cortex.

The cerebellum has connexions with many other parts of the nervous system. Its principal connexions are with the cerebral hemisphere of the opposite side and with the brain stem. It also receives fibres from the spinal cord and is connected with the reflex centres of sight in the roof of the mid-brain, with the thalamus and with the auditory or acoustic nerve of hearing.

The function of the cerebellum is to regulate posture and postural activities. It plays an important part in muscular co-ordination and the maintenance of balance. Whereas the cortico-spinal fibres running between the cerebral cortex and the spinal cord cross (see above), and thus the cerebral cortex controls the movement of the opposite side of the body, the cerebellar hemisphere controls muscle tone and posture on its own side.

A unilateral lesion of the cerebellum causes disturbance of posture and muscle tone. Movement is very inco-ordinate, a patient may be unable to put food into his mouth and smears it across his face; he sways in walking and tends to fall towards the affected side. All voluntary movement is slow, and the muscles of the limbs are limp and flail-like. Speech is slow.

THE CRANIAL NERVES

There are twelve pairs of cranial nerves. Some are mixed nerves, i.e. both motor and sensory, some motor only, and some sensory nerves, e.g. the nerves of the special senses.

- (1) Olfactory (sensory), the nerve of smell. (See also pages 369-70).
- (2) Optic (sensory), the nerve of sight. (See also pages 371-77).
- (3) Oculo-motor nerve supplies most of the external nerves to supply the ciliary muscle and the muscles of the iris. Clinically complete division of this nerve results in ptosis, squint, and loss of the reflexes to light and accommodation.
- (4) Trochlear (motor), to one muscle of the eye, the external oblique.
- (5) **Trigeminal.** This is the largest cranial nerve. It is principally a sensory nerve, supplying most of the skin of the head and face; the membranes of the mouth, nose and paranasal sinuses and the teeth and, by means of a small motor branch, the muscles of mastication. It is divided into three main branches, passing forwards from the trigeminal ganglion: the ophthalmic, maxillary and mandibular nerves, to supply sensation to the respective areas of the face, mouth, teeth and part of the scalp as indicated in Fig. 22/10. It is also concerned with supplying taste sensation to the tongue.

THE CEREBROSPINAL NERVOUS SYSTEM

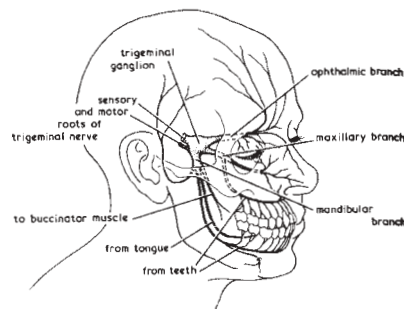


FIG. 22/10. - DISTRIBUTION OF THE TRIGEMINAL (5TH CRANIAL) NERVE

Clinical Notes

Herpes, involving the ophthalmic branch, is serious when it invades the cornea and results in scarring, as this may cause partial or complete blindness. Any herpetic lesion may result in post-herpetic

neuralgia characterized by persistent serve pain. Much more rarely post-herpetic encephalitis may occur.

Trigeminal neuralgia may affect the distribution of one or all of the three branches. The pain is acute and paroxysmal, and in some cases very prostarting. The condition can be relieved by certain surgical measures, but this numbs the face and causes discomfort and is not lightly undertaken.

(6) *Abducens* (motor), to one muscle of the eyeball, the lateral rectus.

(7) *Facial*. This nerve is mainly motor to the muscles of expression of the face, and to the scalp (see Fig. 22/11). It is a sensory nerve in that it is concerned with conveying taste sensation from the tongue.

THE CRANIAL NERVES

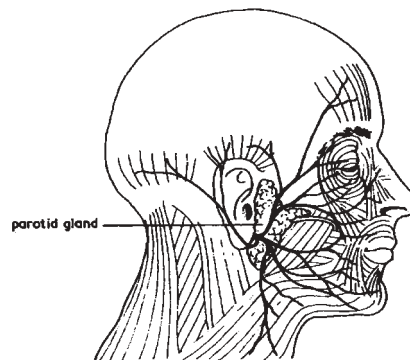


FIG. 22/11 - DISTRIBUTION OF THE FACIAL (7TH CRANIAL) NERVE TO THE MUSCLES OF THE FACE

Clinical aspects. Paralysis of the facial nerve may be due to a number of causes, including fractures of the skull, tumours and poliomyelitis affecting the brain stem.

Bell's palsy is an acute lower motor nerve lesion. The affected side of the face is motionless, the eye stays open, tears flow over the face, food accumulates in the cheek. Little is known of the cause of Bell's palsy. Most cases recover completely.

(8) *Auditory of Acoustic* (sensory), the nerve of hearing. This nerve is in two parts, the cochlear nerve, the true nerve of hearing, and the vestibular nerve, which is concerned with equilibrium.

- (9) *Glosso-pharyngeal* contains motor and sensory fibres. It is motor to one of the constrictor muscles of the pharynx, secreto-motor to the parotid gland and sensory to the posterior third of the tongue and part of the soft palate.
- (10) The Vagus nerve is composed of motor and sensory fibres: its functions are mentioned on page 362. (See also Fig. 23/2, page 365).
- (11) Spinal Accessory. This nerve divides into two parts; one accompanies the vagus, passing to the larynx and pharynx, and the other is a motor nerve to the sternomastoid and trapezius muscles.
- (12) Hypoglossal (motor), to the muscles of the tongue.

THE SPINAL CORD

The spinal cord begins at the medulla oblongata where it emerges from the foramen magnum and ends between the first and second lumbar vertebrae, where it tapers as the conus medullaris and from this a thin prolongation of the pia mater, the filum terminale which has pierced the dural sac, runs to the coccyx. The cord is about 45 cm (18 inches) long, divided in front by a deep anterior fissure and by a narrow one at the back (see Fig. 22/12). See also Clinical Notes,

The cord has two enlargements, cervical and lumbar, from which emerge the nerve plexuses to supply the upper and lower limb; those from the thoracic region form the intercostal nerves.

A transverse section of the cord (see Fig. 22/12) shows the arrangements of grey matter in the form of a letter H. The

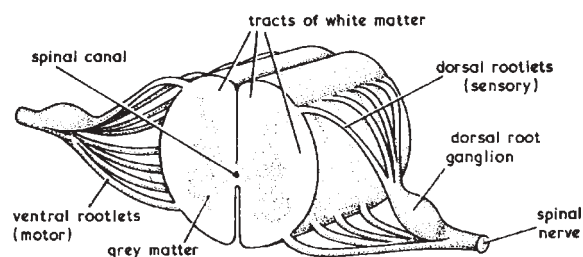


FIG. 22/12 - DIAGRAM OF A SECTION OF THE SPINAL CORD.

spinal canal, with its cerebrospinal fluid, passes through the centre.

The cauda equina is so called from its resemblance to a tail

cauda and quina - of a horse (see Fig. 22/13); it is the sheath of roots of the spinal nerves passing down the spinal canal from their attachment to the spinal cord to their point of emergence through the intervertebral foramina.

The functions of the spinal cord are (a) communication between the brain and all parts of the body, and (b) reflex action.

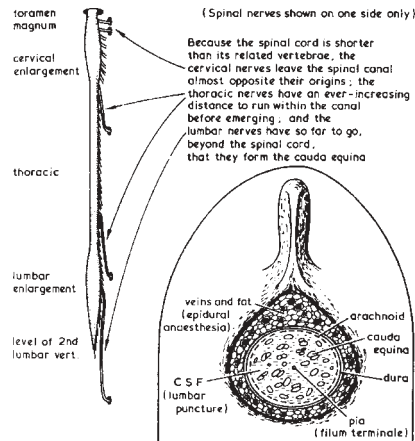


FIG. 22/13 - THE SPINAL CORD. THE INSET SHOWS A TRANSVERSE SECTION OF THE SPINAL CANAL IN THE FOURTH LUMBAR VERTEBRA.

Spinal Nerves. The thirty-one pairs of spinal nerves arise segmentally by two roots, anterior and posterior. Motor nerve fibres forming an anterior root unit with the sensory nerve fibres of a posterior root to form a mixed spinal nerve (see Fig. 22/12). This union takes place before the nerve passes through the intervertebral forame, but soon after emerging it divides again into anterior and posterior primary divisions.

The posterior primary divisions supply the skin and muscles of the back; the anterior primary divisions form branches which become the nerve plexuses for the limbs (see page 352) and, in the thoracic region, the intercostal nerves, already mentioned.

See Clinical Note on lesions of these peripheral nerves, page 358. (See also motor and sensory pathways, pp. 338-9, 348-50).

A Reflex Action requires the following structures which form a reflex arc:

A sensory organ which receives the impulse, e.g. the skin.

A *sensory nerve fibre* which conducts this impulse to the cells in the posterior root ganglion and thence by their fibres to the grey matter of the posterior horn of the spinal cord.

The *spinal cord* where connector nerves pass impulses on to the anterior horn of the cord.

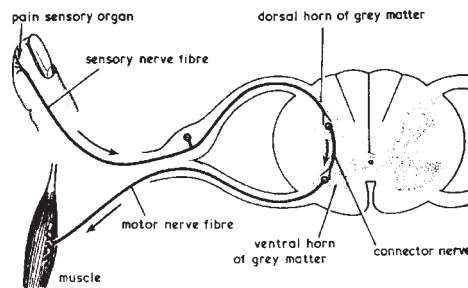


Fig. 22/14 - Diagram of the Parts Required in the Formation of a Reflex Arc

A *motor nerve cell* in the anterior horn of the spinal cord which received and transmits the impulse along motor nerve fibres.

A motor organ, e.g. a muscle, which, stimulated by the motor nerve impulse, performs the action.

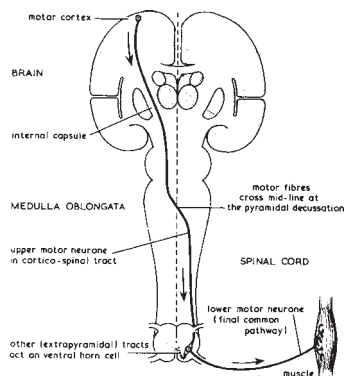


FIG. 22/15. - THE MOTOR NERVE TRACT

Upper motor nerves commence in the cerebral cortex and pass into the spinal cord, crossing at the medulla. As indicated, these nerves cross to pass, closely packed together with the nerves of the ascending sensory tract, through the internal capsule (see page 338) (see also Clinical Note, page 353, on the result of a cerebrovascular accident in this area).

Lower motor nerves begin as cells in the grey matter of the cord, and pass out from the anterior horns to supply the muscles and other structure.

Reflex actions are part of the defence mechanism of the body, and take place much more rapidly than voluntary actions, e.g. the closing of the eye when irritated by dust, the movement of withdrawing the hand from some article accidentally touched if unpleasantly hot. Reflex actions

can be inhibited by voluntary control; the hand instead of being withdrawn may, for example, be held deliberately in contact with the hot surface.

The motor Nerve pathways. Impulses travel in descending tracts called the cerebrospinal or pyramidal tracts, from the cerebral cortex to the spinal cord. The first neurones, upper motor neurones, have their cell bodies in the pre-Rolandic area of the cerebral cortex (see Fig. 22/15) and many fibres converge to be closely grouped together as they pass between the caudate and lentiform nuclei, in the internal capsule.

The lower motor neurones, which begin as cell bodies in the anterior horn of the spinal cord (see Fig. 22/14), pass out in the anterior root of a spinal nerve to be distributed to the periphery, ending in a motor organ such as a muscle.

Motor neurone lesions. In considering the clinical aspect, it is necessary to differentiate between a lesion of an upper motor neurone, i.e., of the central motor pathway and a lesion of a lower motor neurone.

In an *upper motor neurone lesion* - hemiplegia is an example (see Clinical Note, page 357) - the muscles are not paralysed but are weak and control of them is lost. The muscles of the limbs may be spastic and involuntary movements may occur which are uncontrollable and often lead to severe rigidity in spasm. Reflexes are exaggerated. There is no loss of muscle tone and no wasting of the affected muscles.

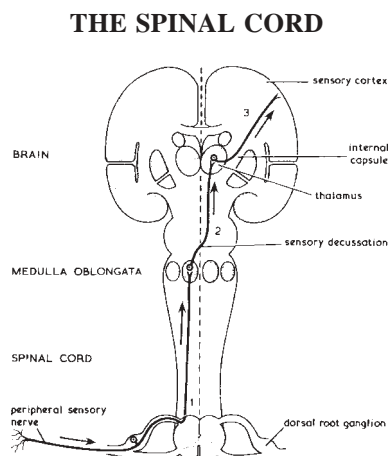


FIG. 22/16. - THE SENSORY NERVE TRACT HAS THREE RELAYS.

1. From the periphery of the spinal cord, the axons ascend as far as the nuclei in the medulla.
2. From the grey matter of the medulla to the thalamus.
3. From thence to the post-Rolandic sensory area (see Fig. 22/7)

In a *lower motor neurone lesion*, as in poliomyelitis, the affected muscles are paralysed, being limp and flaccid, there is wasting and normal reflexes are lost, if the subject is a child the limb may not develop.

Sensory Nerve Pathway. The sensory nerve impulses travel in ascending tracts which consist of a three-neurone pathway.

The *first or most peripheral neurone* has its cell body in the sensory ganglion of the posterior nerve root of a spinal nerve; one branch, a dendron, passes to the periphery to end in some sensory organ such as the skin the other branch, the axon, passes into the spinal cord and ascends in the posterior column to arborize round a nucleus in the medulla.

The second neurone cell arises in the same nucleus and then crosses the mid-line in a similar way as the descending motor pathway (see Fig. 22/16), to form the sensory decussation, ascends through the pons and mid-brain to reach the thalamus.

The third and final neurone commencing in the thalamus passes through the internal capsule to reach the sensory area of the cerebral cortex.

These ascending tracts convey impulses of touch, joints position and vibration sensation; others convey impulses of touch, pain and temperature.

Sensation. Thus a peripheral sensory nerve as depicted in Fig. 22/17 will carry some 'afferent' impulses to be interpreted by the sensory area in the cerebral cortex as touch, pain itch, temperature and warm and cold sensations from superficial structures, and other 'afferent' impulses arising from deeper structures as in pain, pressure etc. and the sense of the movement and the position of joints

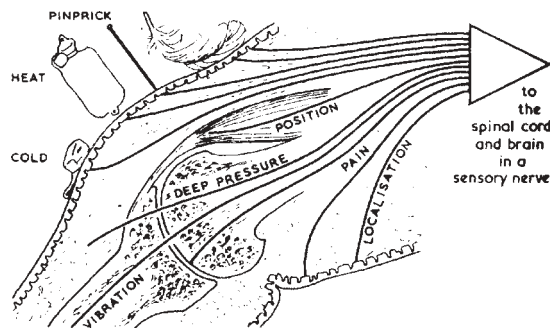


FIG. 22/17. - A DIAGRAM SHOWING THE VARIETIES OF SENSATIONS COLLECTED FROM SUPERFICIAL AND DEEP STRUCTURES.

and muscles. The interpretation of sensation therefore depends on stimuli from the periphery, relayed by several neurones reaching eventually the central interpreting station in the brain.

Nerve synapse. It has been noted (see page 327) that the axon of a nerve is the emitting fibre and the dendrites (there are more than one) the fibres which receive the nerve impulses system impulses may be passed along relays of neurones, as instanced on the ascending sensory neurones, Fig. 22/16. It is considered that the process of passing an impulse on is effected without actual continuity of structure. This process is indicated in the accompanying diagram where the synaptic junction, as it is called, is shown.

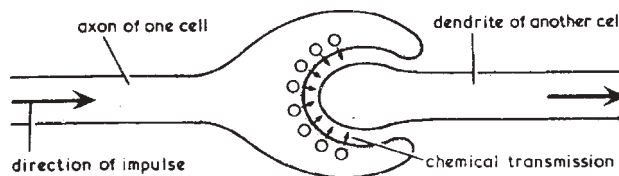


FIG. 22/18. - NERVE SYNAPSE

THE MAIN NERVE PLEXUSES AND THEIR TRUNKS

The anterior primary divisions of the spinal nerves, other than those which arise in the thoracic region and form the intercostal nerves, are arranged into four main plexuses.

The Cervical Plexus is formed by the first four cervical nerves. It lies in the neck beneath the sternomastoid muscle. Many branches arise from it to supply some of the muscles of the neck. The phrenic nerves which supply the diaphragm arise from the plexus.

The Brachial Plexus is formed by the four lower cervical nerves and the first thoracic nerve. It is situated in the posterior triangle of the neck behind the clavicle and in the axilla. At first, three trunks are formed; these then divide and unit again to form three cords, lateral, medial, and posterior. From these cords 5 principal nerves arise which supply the arm and some of the neck and chest muscles (see Fig. below).

The Lumbo-Sacral Plexus (see Fig. 22/20) provides the principal spinal nerves to the lower limb.

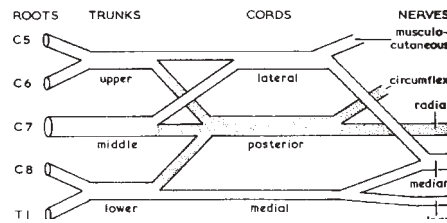


FIG. 22/19 - THE BRACHIAL PLEXUS (LEFT) SHOWING THE ORIGIN OF THE PRINCIPAL NERVES OF THE UPPER LIMB

The Lumbar Plexus from the first 4 lumbar nerve roots lies in the psoas muscle supplying it and divides into two branches, the femoral nerve passing beneath the inguinal ligament, through the femoral triangle (see page 145) to supply the muscles on the front of the thigh, and the obturator nerve which enters the thigh through the obturator foramen to supply the muscles on the inner side of it.

The Sacral plexus consists of the 4th and 5th lumbar nerves and the sacral nerves uniting to form the great sciatic nerve which passes into the thigh through the great sacral notch supplying the hamstring muscles. It then divides into the medial and lateral popliteal nerves (see Fig. 22/23) which supply the muscles on the back of the thigh and all the muscles, back and front, below the knee.

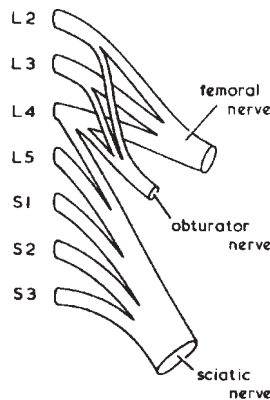


FIG. 22/20. - THE LUMBO-SACRAL PLEXUS, SHOWING THE ORIGIN OF THE PRINCIPAL NERVES TO THE LOWER LIMB

Clinical Notes

Clinical nerves. Disease or damage to the cranial nerves causes the following symptoms:

- i. Loss of smell
- ii. Dimness or loss of vision
- iii.iv.vi. Double vision, squint
- v. Pain or loss of feeling on the face, toothache, and weakness of mastication (see Clinical Note, page 342)
- vii Paralysis of the facial muscles (see Clinical Note. page 343)
- viii Auditory deafness or tinnitus, vestibular giddiness, loss of balance
- ix,x,xi. Difficulty in swallowing
- xii. Weakness of the tongue, causing difficulty in chewing and speaking

Cerebral hemipheres.

Cerebral lesions. The disease or damage which presents after injury, or following a cerebrovascular accident to the brain, depends on the areas

THE CEREBROSPINAL NERVOUS SYSTEM

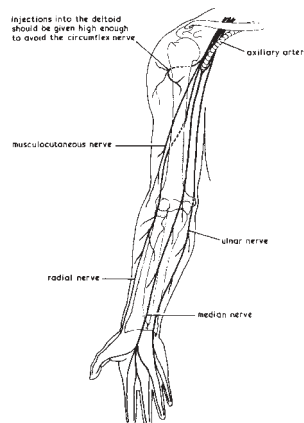


FIG. 22/21. - SHOWING THE MAIN NERVES ARISING FROM THE BRACHIAL PLEXUS

The radial nerve may be damaged in fracture of the humerus, when the branch supplying the extensors of wrist and fingers may be injured or for any other cause put out of action.

The result is wrist drop which requires splintage and physiotherapy.

Injury to the median nerve will destroy sensation to the skin of first 3 1/2 digits, and to the ulnar nerve half the ring finger and the little finger (1 1/2 digits). Wasting and loss of power in the muscles of the thenar and hypothenar eminences and in the small muscles of the palm result from injury to these two nerves.

THE MAN NERVE PLEXUSES

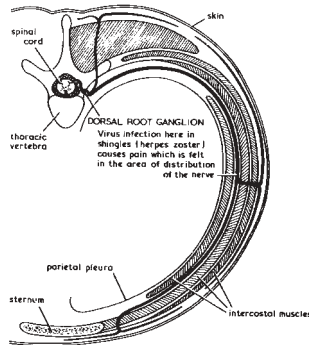


FIG. 22/22 - DIAGRAM OF THE COURSE OF THE SENSORY PART OF A THORACIC NERVE

THE CEREBROSPINAL NERVOUS SYSTEM

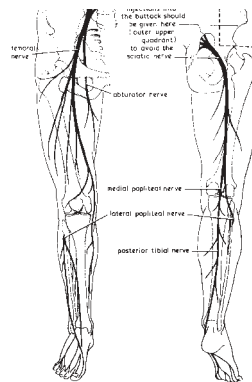


FIG. 22/23 - THE PRINCIPAL NERVES FROM THE LUMBO-SACRAL PLEXUS (SEE FIG. 22/20) INDICATING THEIR COURSE THROUGH THE LOWER LIMB CONTD. FROM P. 353)

and neurones involved: motor and sensory nerves pass through the internal capsule (see pages 338, 347) on their journey to and from the brain, so both may be affected.

Motor paralysis of the spastic type with muscular rigidity and increased reflexes follows involvement of the upper motor neurones (see page 348). This may affect only the arm and leg of one side - hemiplegia-but muscles of the face, head, neck and trunk, though the latter often escapes, may also be involved.

Sensory paralysis follows injury to the sensory path. Reflex actions are abnormal. These involved the organic reflexes of the pupil of the eye, which may be contracted, or fail to contract; the reflexes of the bladder are affected causing paralysis of the sphincters and the bladder wall which results in retention of urine with overflow;

involvement of the rectum, with disorder of the reflex of defecation, may also occur and these matters are of great practical importance in nursing care.

As the cerebral hemispheres are also the part of the brain in which highly developed functions such as speech, vision, taste and smell and memory are situated, damage can cause many symptoms.

Cerebral lesions, need the services of an experienced physiotherapist in order to re-educate and train the parts which remain and initiate other tracts to function. It also needs the continuous interest and co-operation of doctors and nurses, and most important too the full collaboration of the patient and his relatives in order to ensure the highest degree of rehabilitation possible for him.

Basal ganglia. Parkinson's disease, paralysis agitans or shaking palsy is thought to be due to degeneration of the basal ganglia (see Clinical Note, page 337).

Lesions in one of the cerebellar hemispheres give rise to symptoms on the same side of the body (see Clinical Note, page 341).

Brain stem, pons and medulla. The vital centres controlling breathing and blood pressure are located here, so severe damage causes death. The number of nervous pathways concentrated in this region is so great that even small lesions cause much weakness and loss of feeling.

Spinal cord lesions

Division or transection of the spinal cord due, most often, to a traffic accident, is a serious injury which may be complete or partial. A complete transection is considered here. The higher the injury, the greater is the disablement. In the cervical region arms, trunk and legs are affected (the patient is helpless). When the phrenic nerve escapes, the diaphragm may be unaffected; if involved artificial respiration is needed until a mechanical respirator can be employed.

A transection in the dorsal and lumbar regions results (in the dorsal) in paralysis of the intercostal muscles, the abdominal muscles and in those of both the lower limbs with involvement of the sphincters of urethra and rectum (see page 358).

Spinal shock occurs at first, lasting for about a week. The muscles of the areas below the injury are limp and flaccid, as in a lower

motor neurone lesion (see page 348); all reflexes are abolished, there is incontinence of urine and faeces. During this stage there is complete anaesthesia of all areas below the lesion, with danger of injury to the skin, so that expert routine nursing care is essential.

Spasticity and rigidity. The state of flaccid paralysis passes, muscles regain tone but are weak, the affected limbs become rigid and spastic, reflex movements, particularly affecting flexor and adductor muscle groups, occur, but there is no voluntary control over these movements. This power is lost. At this stage deformities are likely to occur.

The condition of the bladder and rectal function needs watching. Complete urinary incontinence gives place to retention of urine with overflow, when either regular catheterization or continuous bladder drainage will be employed as residual urine in the bladder is a source of infection which may spread to the entire urinary tract.

With a co-operative patient it may be possible to establish automatic reflex bladder and bowel action.

Similar symptoms may arise in any conditions causing interruption of the spinal cord such as pressure by a tumour, or in neurological disease such as multiple sclerosis.

A patient facing the grave disability brought about by a transection of the spinal cord needs all the understanding and help we can give, for his collaboration is essential. It is ideal if he can be nursed in a special 'spinal' unit, such as that at Stoke Mandeville, where his needs will be understood, all facilities provided for moving, and recreational, educational and occupational measures geared to the best possible degree of rehabilitation for him; a remarkable amount can be achieved.

Peripheral nerve lesions may be due to pressure on a nerve root or roots, causing inflammation (radiculitis). Some disorder of the spine, an intervertebral disc lesion, spondylosis, tumour and spinal fracture may be the cause. The presence of a cervical rib, causing brachial neuritis is mentioned on page 76. An intervertebral disc lesion is a common cause of sciatic neuritis (sciatica).

Division of any of these mixed nerves, which may occur in road accidents, will deprive the areas supplied by them of the power of movement as this constitutes a lower motor neurone lesion (see also

page 348) and of sensation. Peripheral nerve injuries can surgically repaired, but it takes a long time for one of the principal nerves of a limb to grow and regenerate; in the meantime, physiotherapy is employed to assist the process and keep the affected muscles in tone.

Neuritis is a composite term used to indicate disorder of a peripheral nerve from any cause, whether inflammation, some form of poisoning, as in alcoholic neuritis, or pressure. Symptoms of the inflammatory type are variable; there is usually pain which is worse at night and not relieved by rest. Disturbances of sensation include numbness and tingling; in some instances paralysis occurs. In polyneuritis the condition is symmetrical-examples include alcoholic neuritis, diabetic neuritis and neuritis due to metabolic disturbances including dietetic and vitamin deficiencies, for example in beri-beri.

When due to pressure there is generally paresis or paralysis, but pain may not be constant. This type is named after plexus or nerve involved as:

Brachial plexus neuritis may be due to infection, injury or pressure.

Radial nerve neuritis (see note on page 354, Fig. 22/21). The radial nerve may be injured if the arm is allowed to hang over the side of a stretcher or operating table.

Ulnar nerve pressure may arise from leaning on the elbow in lying.

Median nerve compression in the carpal tunnel is mentioned on page 97.

Sciatic neuritis - sciatica is thought in many cases to be due to pressure from a prolapsed intervertebral disc or other lesion of the lower part of the vertebral column.

The lateral popliteal nerve may be compressed when the leg is in plaster of paris as it winds round the head of the fibula (see Fig. 22/23, page 356).

Encephalitis is inflammation of the substance of the brain and is usually due to viral infection.

Meningitis is inflammation of the meninges of the brain (see Clinical Note on page 331).

Neuro-surgery is a highly specialized branch which includes all operations undertaken on the brain, spinal cord, and the peripheral

nerves. (Careful pre-operative investigations are carried out in order to determine the exact site of the lesion or tumour, to assess as far as possible the prognosis, and to decide what after-care and follow-up will be necessary.

Craniotomy is opening the skull, generally to deal with a tumour, blood or blood-clot, or a depressed fracture of the vault, causing pressure on the brain. This subject is too comprehensive to be dealt with here; but the reader is referred to the clinical notes on head and to those on spinal cord and peripheral nerve lesions dealt with above.

THE AUTONOMIC NERVOUS SYSTEM

The autonomic nervous system is dependent on the central nervous system with which it is connected by afferent and efferent nerves. It behaves as if it were a part of the central nervous system which had migrated from it in order to reach glands, blood vessels, heart, lungs and intestine. Because the autonomic nervous system deals mainly with involuntary or automatic nervous control of viscera it is sometimes called the involuntary nervous system. The autonomic nervous system is divided functionally into two parts :

- (a) the sympathetic system (see below) which lies in front of the vertebral column and is associated and connected with the spinal cord by nerve fibres.
- (b) the parasympathetic system which is divided into two parts composed of the cranial and sacral autonomic nerves (see Fig. 23/2)

The Sympathetic System consists of a double chain of ganglionated cords extending from the base of the skull, lying in front of the vertebral column, to end in the pelvis opposite the coccyx as the ganglion impar these ganglia are arranged in pairs and distributed from the following regions:

In the neck:	Three pairs of cervical ganglia
In the chest :	Eleven pairs of thoracic ganglia
In the lions :	Four pairs of lumbar ganglia
In the pelvis :	Four pairs of sacral ganglia
Front of coccys :	The ganglion impar.

These ganglia are intimately connected with the central nervous system through the spinal cord by means of communicating branches, which pass outwards from cord to ganglia, and inwards from ganglia to cord.

Other sympathetic ganglia are placed in relation to these two great chains of ganglia and with their fibres from the sympathetic plexuses (see Fig. 23/1).

(1) *The cardiac plexus* is placed near the the base of the heart and sends branches to it and to the lungs.

(2) *The coeliac plexus* lies behind the stomach and supplies organs in the abdominal cavity.

(3) *The mesenteric plexus* lies in front of the sacrum and supplies organs in the pelvis.

THE AUTONOMIC NERVOUS SYSTEM

The autonomic nervous system is dependent on the central nervous system with which it is connected by afferent and efferent nerves. It behaves as if it were a part of the central nervous system which had migrated from it in order to reach glands, blood vessels, heart, lungs and intestine. Because the autonomic nervous system deals mainly with involuntary or automatic nervous control of viscera it is sometimes called the involuntary nervous system. The autonomic nervous system is divided functionally into two parts :

- (a) the sympathetic system (see below) which lies in front of the vertebral column and is associated and connected with the spinal cord by nerve fibres.
- (b) the parasympathetic system which is divided into two parts composed of the cranial and sacral autonomic nerves (see Fig. 23/2)

The Sympathetic System consists of a double chain of ganglionated cords extending from the base of the skull, lying in front of the vertebral column, to end in the pelvis opposite the coccyx as the ganglion impar. These ganglia are arranged in pairs and distributed from the following regions:

In the neck:	Three pairs of cervical ganglia
In the chest :	Eleven pairs of thoracic ganglia
In the lumbar :	Four pairs of lumbar ganglia
In the pelvis :	Four pairs of sacral ganglia
Front of coccyx :	The ganglion impar.

These ganglia are intimately connected with the central nervous system through the spinal cord by means of communicating branches, which pass outwards from cord to ganglia, and inwards from ganglia to cord.

Other sympathetic ganglia are placed in relation to these two great chains of ganglia and with their fibres from the sympathetic plexuses (see Fig. 23/1).

(1) *The cardiac plexus* is placed near the base of the heart and sends branches to it and to the lungs.

(2) *The coeliac plexus* lies behind the stomach and supplies organs in the abdominal cavity.

(3) *The mesenteric plexus* lies in front of the sacrum and supplies organs in the pelvis.

Functions. Sympathetic nerves supply innervation to the muscle of the heart, the involuntary muscle of all blood vessels, and of viscera such as the stomach, pancreas and intestines. It supplies motor secretory fibres to the sweat glands, arrectors pilorum - and maintains the tone of all muscle, including the tone of voluntary muscle.

The Parasympathetic System. The Cranial Autonomics are the third, seventh, ninth and tenth cranial nerves. These form the means by which the parasympathetic fibres pass out from the brain to the organs partly controlled by them.

By means of the *third cranial nerve*, the oculomotor nerve, fibres reach the circular muscular fibres of the iris, stimulating the movements which determine the size of the pupil of the eye.

By the *seventh nerve*, the facial, and the ninth, the glossopharyngeal, motor secretory fibres reach the salivary glands.

The *vegas or tenth cranial nerve* is the largest autonomic nerve. It has a very wide distribution and sends fibres to a number of glands and organs as indicated in Fig. 23/2. This distribution is closely associated with that of the sympathetic fibres (see system of dual control of certain organs below).

The *Sacral Parasympathetic Nerves* pass out from the sacral region of the cord. These form the nerves to the pelvic viscera and together with the sympathetic nerves form the plexuses which supply the colon, rectum and bladder.

A System of Dual Control (sympathetic and parasympathetic). Although some organs and glands have only one source of supply, sympathetic or parasympathetic, these are in the minority; the majority have a dual supply, receiving some fibres from the sympathetic system and some from the cranial or sacral autonomic nerves, the activity of

the organ being stimulated by one set of nerves and retarded or inhibited by the other set—each acting in antagonism to the other. In this way an exact adjustment is maintained between activity and rest, and the smooth rhythmic action of the internal organs, glands, blood vessels, and involuntary muscle is maintained.

Thus the heart receives accelerator fibres from the sympathetic nerves, and inhibitory fibres from the vagi.

The blood vessels have their vasoconstrictors and vasodilators.

The alimentary canal has accelerator and inhibitory nerves, which increase and decrease peristaltic movements respectively.

<i>Organ</i>	<i>Action increased of Activated by:</i>	<i>Action depressed of Inhibited by:</i>
<i>Heart</i>	Sympathetic (rate and force increased)	Vagus(rate and force decreased)
<i>Bronchi</i>	Vagus (constricted)	Sympathetic (dilated)
<i>Stomach</i>	Vagus(constricted)	Sympathetic (relaxed)
<i>Intestine</i>	Vagus(constricted)	Sympathetic (relaxed)
<i>Bladder</i>	Sacralautonomic (constricted)	Sympathetic (relaxed)
<i>Pupil of eye (iris)</i>	3rd cranial autonomic (constricted)	Sympathetic (dilated)

In the case of an organ which possesses a sphincter muscle, such as the stomach in the pyloric sphincter, the intestine in the ileocolic sphincter, and the bladder in the internal urethral sphincter, the nerve which causes contraction of the organ inhibits the sphincter and vice-versa. For example, in the act of micturition the urethral sphincter is relaxed whilst the muscle in the wall of the bladder is contracted thus enabling the bladder to be emptied.

364 THE AUTONOMIC NERVOUS SYSTEM

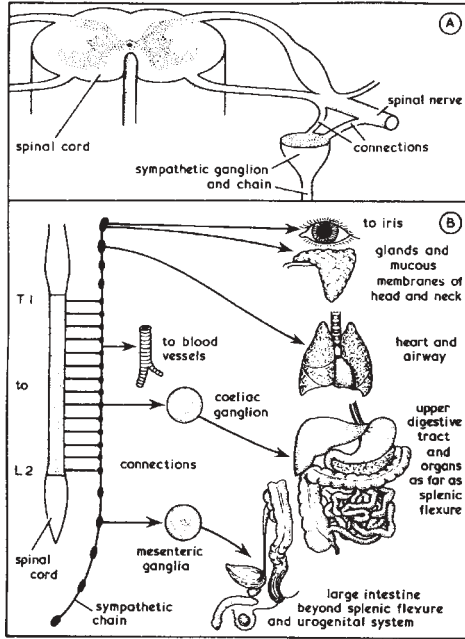


FIG. 23/1.—(A) THE CONNECTIONS BETWEEN SPINAL CORD, SPINAL NERVE AND SYMPATHETIC CHAIN (B) DIAGRAM OF ONE GANGLIONATED CORD OF THE SYMPATHETIC SYSTEM, THE PRINCIPAL PLEXUSES AND SOME OF THE ORGANS SUPPLIED BY THEM

THE AUTONOMIC NERVOUS SYSTEM 365

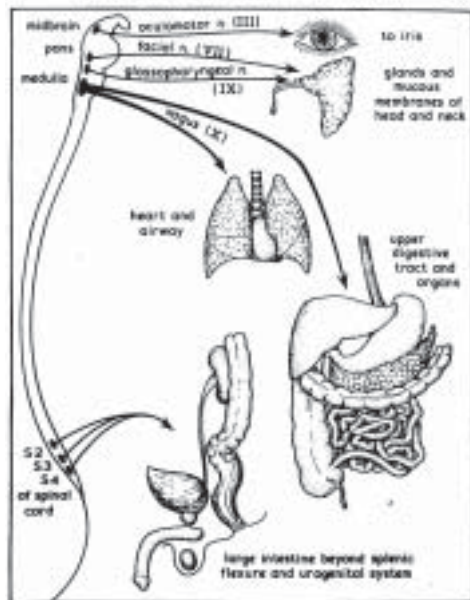


FIG. 23/2.—THE PARASYMPATHETIC SYSTEM. DIAGRAM OF THE ORGANS SUPPLIED BY THE CRANIAL AND SACRAL AUTONOMIC NERVES

Body Changes during exercise

1. Blood flow in skeletal muscles during exercise

Blood flow in the muscles can increase more than 20 times than normal during exercise.

During rest blood flow through skeletal muscles is 3 to 4 ml / min / 100 gm of muscle. During strenuous exercise, the rate can increase 15-25 times rising to 50 - 80ml/100gm of muscle.

During rest some of the capillaries have little or no flowing blood. But during strenuous exercise, all capillaries open up. This opening up of dormant capillaries also diminished the distance that oxygen and other nutrients must diffuse from the capillaries to the muscle fibers and callaries a 2-3 times increased surface area through which nutrients can diffuse from the blood.

2. Respiration in exercise :

Normal oxygen consumption for a young man is about 250ml/ min. In maximal exercising conditions it may be increased up to "3600 to 5100 ml/min". Because of great usage of oxygen by the muscles during exercise, diffusion rates between the capillaries will increase. Respiratory rate increases and there will be a hyper ventilation.

3. Cardio - vascular system in exercise :

Cardiac output increases during exercise. In average young man at rest cardiooutput is 5.5 lit/min. It will increase up to 30 liters / minute.

Marathoners (long distance runners) Cardiac output will be 40% greater than untrained persons.

There will be hypertrophy of the Cardiac muscles due to prolonged "exercise training".

Stroke volume increases from 105 to 162 milliliters.

Heart rate increases from 50 to 185 beats / min.

8. RESPIRATORY SYSTEM

RESPIRATION :

Respiration is defined as the exchange of gases between body tissues and the external environment. Supply of oxygen to the tissues and excretion of carbon dioxide occur only through respiration. The functions of respiration are:

1. Transport of oxygen to tissues and excretion of carbon dioxide.
2. Excretion of volatile substances like ammonia.
3. Regulation of temperature through loss of heat in the expired air.
4. Maintenance of pH of blood.
5. Regulation of water balance through excretion of water vapour.

RESPIRATORY SYSTEM: The respiratory system consists of the following structures:

- 1) Nasal cavity
- 2) Pharynx
- 3) Larynx
- 4) Trachea
- 5) Bronchi
- 6) Bronchioles
- 7) Alveoli.

1. Nasal cavity:

It is divided into right and left portions by means of *nasal septum*. The nasal cavity is lined by mucous membranes. The entrance to nasal cavity is formed by "anterior nares" (nostrils). They contain small hairs which act as filters for dust. The back of nasal cavities contain posterior nares. They form the entrance to nasopharynx.

2. Pharynx: It is divided into three parts:

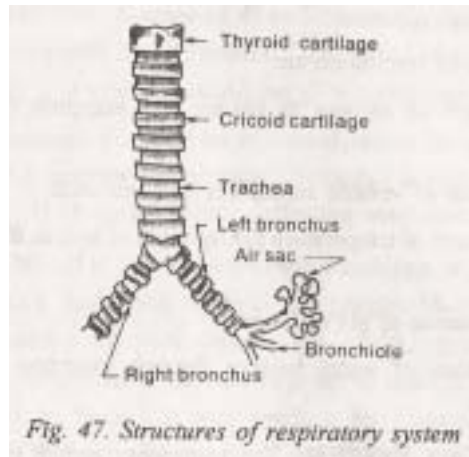
- i) *Nasopharynx* which lies behind the nasal cavities. It contains openings for Eustachian tubes on the lateral wall.

3. Larynx :

It lies between pharynx above and trachea below. It is formed by the following cartilages:

- i) "Thyroid cartilage" which is the largest.
- ii) "Cricoid cartilage" which lies below the thyroid cartilage.

- iii) "Two aretenoid cartilages" at the back of cricoid.
- iv) "Epiglottis" attached to the top of thyroid cartilage



4. Trachea (Wind pipe) :

It is a cylindrical tube which is about 11 cm. in length. It begins at the lower end of pharynx. At the level of 5th thoracic vertebra, it divides into two bronchi. Trachea is made of sixteen to twenty C-shaped incomplete cartilages. These cartilages are connected by fibrous tissue at the back. The trachea is lined by mucous membrane made of ciliated epithelium.

5. Bronchi:

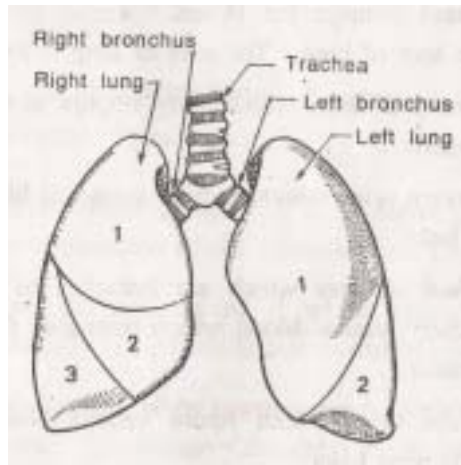
The trachea ends by dividing into two bronchi namely right and left bronchi. They pass to the corresponding lung. The right bronchus is shorter and wider than the left. Bronchi are made of complete rings of cartilage.

6. Bronchioles:

They are formed by the division of bronchi. Bronchioles are the finest branches of bronchi. Bronchioles do not have cartilage. They are lined by cuboidal epithelium.

7. Alveoli(Air sacs):

They are the final termination of each bronchi. They contain a thin layer of epithelial cells surrounded by numerous capillaries. Exchange of gases takes place through the walls of these capillaries.



THE LUNGS :

Lungs are the principal organs of respiration. They are two in number lying one on each side of the chest cavity. The two lungs are separated in the middle by heart and other structures of mediastinum.

Shape:

Lungs are conical in shape. The apex of lungs is above, rising slightly over the clavicle. The base of lungs is near the diaphragm.

Lobes:

Each lung is divided into lobes by means of fissures. The right lung which is bigger has three lobes. The left lung has two lobes. Each lobe is composed of a number of lobules. Each lobe contains a small bronchial tube. This tube divides and sub divides and ends finally in air sacs.

Pleura:

It is a serous membrane which covers the lungs. It is made of two layers. The inner layer is called as *visceral layer*. It is very close to the lungs. "Parietal layer" is the outer layer. The space between these two layers is filled with pleural fluid.

Root of the lungs:

The medial surface of each lung has a vertical slit called hylum. Structures like blood vessels, nerves and lymphatics pass

through the hylum. These structures together constitute the root of lung. The root of lung is formed by:

- 1 "Pulmonary arteries" which carry impure blood to the lungs from heart.
- 2 "Pulmonary veins" which carry oxygenated blood from lungs to the heart.
- 3 "Bronchial arteries" which are branches of thoracic aorta. They carry arterial blood which nourishes the substance of lung tissue.
- 4 "Bronchial veins" which return venous blood of lungs to superior vena cava.
5. "Bronchi" which divide into bronchioles.
- 6 "Lymphatic" vessels and lymph glands.
7. Nerves: Sympathetic and vagus nerve which supply the lungs.

Blood vessels of lungs:

1. Pulmonary arteries which carry impure blood from the right ventricle to the lungs. These arteries divided and sub divided to from arterioles ultimately from a network of capillaries. The thin membrane of these capillaries enable exchange of gases which is a function of respiration.

2. Pulmonary veins formed by the union of capillaries. The pulmonary veins carry oxygenated blood to left atrium of heart.

3. Bronchial arteries which carry oxygenated blood from thoracic aorta directly to lungs. This blood nourishes the substance of lung tissue.

4. Bronchial veins which return the venous blood of lungs to superior vena cava.

MECHANISM OF RESPIRATION: Respiration involves two stages: 1) inspiration 2) expiration

Inspiration (or breathing in):

It is an active process. It is produced by the contraction of the following muscles:

1. Diaphragm, the contraction of which enlarges the chest cavity

vertically (i.e., from above downwards).

2. Intercostal muscles when contract produce elevation or ribs and sternum. This enlarges the chest cavity in all the other four sides.
3. The lungs expand at this stage and fill this increased space. Now, the pressure in the lungs is less than atmospheric pressure. So air flows into the lungs.

Expiration (or breathing out):

It is a passive process. It is produced by the relaxation of diaphragm and intercostals muscles. This produced reduction in the size of chest cavity. So the pressure in the lungs increases which forces the air out. The rate of respiration is 16 to 18 per minute in adults. The rate is higher in children.

REGULATION OF RESPIRATION: Respiration is regulated by two controls: 1) Nervous control 2) Chemical control..

1. Nervous control: It is exerted by "respiratory center" present in the medulla oblongata of brain. From this centre afferent impulses pass to:

1. Diaphragm through phrenic nerve.
2. Intercostal muscles through intercostal nerves.

These impulses cause rhythmic contraction of diaphragm and intercostal muscles.

Afferent impulses arise due to the distention of air sacs. They are carried by vagus to the respiratory centre.

2. Chemical control :

This is effected through carbon dioxide content of blood. An increase in the level of carbon dioxide produces stimulation of the respiratory centre. A decrease in carbon dioxide level produces the opposite effect.

REFLEX MECHANISMS

Carotid body and aortic body chemoreceptors: Some chemoreceptors also regulated respiration reflexly. These receptors are present in:

1. "Carotid body" which lies in the bifurcation of common carotid artery.
2. "Aortic body" which is at the foot of subclavian artery.

These two bodies contain the ending of sensory nerve which run in vagus nerves. Increase in carbondioxide level of blood stimulates these bodies. The impulses are then carried to the respiratory centre which is also stimulated.

Hering-Breuer reflex:

The lungs contain some stretch receptors. Expansion of the lungs stimulates these receptors. These impulses now inhibit the respiratory centre. So inspiration stops. Now the lungs collapse and there is no stretch. So inhibition of the respiratory centre through vagus also stops. Inspiration starts again. This reflex is called Hering-Breuer reflex.

RESPIRATORY VOLUMES:

The contraction of diaphragm and intercostal muscles produces expansion of the chest cavity. So air enters into the lungs during inspiration. A forced inspiration can produce additional expansion. So more air can enter the lungs. Similarly, a forced expiration can expel an extra volume of air. Even after a forced expiration, some air still remains in the lungs. The various respiratory volumes are defined as follows:

1. Vital capacity:

It is defined as the volumes of air that can be expelled by a force expiration after a forced inspiration (Normal value is 4 litres).

2. Tidal air :

It is the volume of air passing in and out of the lungs with ordinary quiet breathing (Normal value is 0.5 litres).

3. Inspiratory reserve:

It is the additional volume of air that can be taken in by forced inspiration (Normal value is 2.5 litres).

4. Expiratory reserve:

It is the volume of air that can be expelled by forced

expiration after normal inspiration (Normal value is 1 litre).

5. Residual volume:

It is the volume of air which remains in the lungs on forced expiration after normal inspiration (Normal value is 1 litre).

6. Total lung capacity:

It is the sum of vital capacity and residual volume (Normal value is 5 litres)

EXCHANGE OF GASES : It occurs in two stages:

1. Exchange between tissues and blood,
2. Exchange between alveoli and blood.

1. Exchange between tissues and blood.

This is called as tissue or internal respiration. The oxygen tension of pure blood supplying the tissues is high (100 mm Hg.) But the oxygen tension of tissues is low (40 mm Hg.). So oxygen of blood goes to tissues. The carbondioxide tension is more in tissues than in blood. So carbondioxide goes out from the tissues to blood. Now blood containing more carbondioxide is taken back to the heart by venous system.

2. Exchange between alveoli and blood:

It is called as pulmonary or external respiration. The oxygen tension in the alveolar air is high (1.00 mm Hg). But oxygen tension of blood in the capillaries is low. Due to the pressure difference oxygen of alveoli enters into blood. Similarly carbondioxide tension of capillary blood is higher than in alveoli. So carbondioxide enters into alveoli and it is breathe out through the expired air.

ABNORMAL TYPES OF RESPIRATION

1. Cheyne-stokes breathing:

It is a form of periodic breathing in which groups of breaths are separated by periods of apnea. This occurs because the CO₂ tension of arterial blood is reduced to a very low level. So the respiratory centre can not be stimulated. Respiration starts again, only when the CO₂ tension increases. Cheyne-stokes breathing occurs in uremia, opium poisoning and increased intracranial

pressure.

2. **Apnea** - stopping of respiration for short intervals.
3. **Hyperpnea** - increase in depth of respiration.
4. **Dyspnea** - difficulty in breathing.
5. **Polypnea** - respiration characterised by rapid rate.
6. **Tachypnea** - exceedingly high rate of respiration.

ARTIFICIAL RESPIRATION:

It is employed when respiration fails due to drowning, carbon monoxide poisoning etc. Artificial respiration must be given immediately when respiration fails. Most methods employed are designed to increase and decrease the capacity of thorax. So air can be drawn into the lungs and expelled. The follow are a few methods of artificial respiration:

1. Schafer's method and Holger Nialson method:

Both involve compression of throacic cavity by pressure against ribs.

2. Mouth to mouth method:

It involves blowing air into lungs through mouth.

3 Instrumental methods:

They are Drinker's method, Bragg- Paul's method and Iron lung method. These methods can be carried out only in hospitals.

9. DIGESTIVE SYSTEM

The Digestive System consists of gastro intestinal tract (alimentary canal) and its glands. The functions of the gastrointestinal tract are ingestion, digestion and absorption of food and excretion of waste products.

PARTS OF DIGESTIVE SYSTEM :

Digestive system consists of the following parts :

- | | | |
|-----------|-------------------|-------------------|
| 1.mouth | 2.pharynx | 3.oesophagus |
| 4.stomach | 5.small intestine | 6.large intestine |
| 7.rectum | 8.anus | |

MOUTH (Buccal Cavity)

It is the upper expanded portion which forms the beginning of the alimentary canal. It can be divided into two parts.

1. Vestibule, an outer part. It lies between lips and inner lining of cheeks externally and gums and teeth internally.
2. Cavity of mouth, an inner part. It is bounded by teeth and maxilla at the sides, palate above and tongue below.

Palate forms the roof of mouth cavity. It consists of hard palate which is in front and soft palate which is behind. Uvula is a conical process which hangs from the middle of soft palate. Two folds of mucous membranes called anterior and posterior pillars of fauces lie on either side of uvula. Tonsils lie in between these folds.

The important structures of mouth are

- | | | |
|----------|---------|-------------------|
| 1.tongue | 2.teeth | 3.salivary glands |
|----------|---------|-------------------|

Tongue :

Tongue lies in the floor of the mouth and it is attached to hyoid bone. Tongue contains :

1. A root at which blood vessels and nerves pass
2. A tip which is pointed when the tongue is protruded and rounded when the tongue is in the mouth
3. Two margins which are in contact with lower teeth

4. An upper surface which contains a small elevation called "dorsum".
5. A lower surface which contains a soft ligamentous structure called frenulum.

The two important structures of tongue are :

1. Taste buds which are on the lateral aspects of tongue
2. Three types of papillae present on the upper surface.
They are :
Circumvallate papille, Fungiform papillae and Filiform papillae.

Teeth :

Teeth are concerned with mastication. Depending on the age at which they arise, teeth can be classified into two types :

1. Permanent teeth : the teeth of adult life
2. Temporary or milk teeth : the teeth of childhood

Permanent Teeth :

They are 32 in number and 16 are present in each jaw. Each half of the upper and lower jaw contains 8 teeth. They are : 2 incisors, 1 canine, 2 premolars and 3 molars.

Temporary Teeth :

They are 20 in number and each jaw has 10 teeth. Each half of the jaw has 2 incisor,s 1 canine and 2 molars.

Eruption of Teeth :

Even at birth, all the permanent and temporary teeth are buried in the alveolar process of jaws. The first tooth appears in a child at the 7th month, the full set of temporary teeth is completed at the age of two years.

SALIVARY GLANDS

There are three pairs of salivary glands in the mouth. They are parotid, submandibular and sublingual glands.

Parotid Glands :

One on each side is present below and in front of each ear. Each gland has a duct called Stensons duct. This duct opens on the inner side of cheek opposite to the second upper molar tooth.

Submandibular glands (Submaxillary Glands)

They are smaller than parotid glands. One on each side lies under the angle of jaw. Each gland has a duct called Whartons duct which opens near the mid line under the tongue.

Sublingual Glands :

They are the smallest salivary glands which lie under the tongue. They pour the secretions directly into the mouth through several small openings.

SALIVA

It is a mixed secretion of all the three parts of salivary glands. It is an alkaline fluid containing water to the extent of 99%. The solid contents of saliva are :

1. mucin which is a glycoprotein
2. ptyalin, an enzyme which converts starch into maltose.

Also, it contains salts of sodium, potassium, calcium, and magnesium.

FUNCTIONS

1. It converts cooked starch into a soluble sugar called maltose
2. It acts as a solvent for food and helps in its swallowing
3. It moistens, lubricates and cleans the mouth
4. It excretes organic and inorganic substances and some drugs.

PHARYNX

Pharynx lies between the mouth and oesophagus. Pharynx consists of three parts :

- i. nasopharynx
- ii. oropharynx
- iii. laryngopharynx

Nasopharynx

It lies behind the nasal cavity. It extends from base of skull to the level of soft palate. On either side, it has an opening for Eustachian tube.

Oropharynx :

It lies behind the mouth. It extends between soft palate above and upper opening of larynx below. The lateral walls of oropharynx contain the tonsils.

Laryngopharynx :

It is the lowest part and it lies behind the larynx.

Oropharynx and laryngopharynx serve as a common channel for the passage of food and air. Through both these parts, food is conducted from mouth to oesophagus and air from nasopharynx to larynx.

OESOPHAGUS

It is a muscular tube which extends between pharynx above and cardiac orifice of stomach below. It lies between trachea in front and vertebral column at the back. From the thorax, it enters the abdomen through the oesophageal opening of diaphragm. The oesophagus contains sphincters at its upper and lower ends. These sphincters relax during swallowing.

Deglutition (the act of swallowing) :

In the mouth, food is masticated and mixed well with saliva. The action of tongue and cheeks convert food into a round mass called bolus. This bolus is swallowed.

ABDOMINAL CAVITY AND ITS CONTENTS

Abdomen is the largest cavity in the body. It is oval in shape and contains a variety of organs. It can be divided into two parts

- | | | | |
|----|----------------|---|------------------------|
| 1. | Abdomen proper | - | an upper larger cavity |
| 2. | Pelvis | - | a lower small cavity |

Boundaries of abdomen : Abdomen is bounded :

1. above by the lower surface of diaphragm
2. below by the brim of true pelvis
3. in the front and sides by abdominal muscles, ribs and iliac bones.
4. at the back by vertebral column, psoas and quadratus lumborum muscles.

Contents of abdomen :

The abdomen contains stomach, intestines, liver, spleen, pancreas, kidneys, adrenal glands, abdominal aorta, inferior vena cava, peritoneum, fat etc.

STOMACH AND ITS DIGESTIVE FUNCTION

Stomach is the dilated portion of alimentary canal and it receives food from oesophagus. It lies in the upper part of abdominal cavity below the left half of diaphragm.

Parts of Stomach : Stomach has

1. Two surfaces : an anterior and a posterior surface
2. Two borders : an upper border called lesser curvature, a lower border called greater curvature.
3. Two ends : Upper end called cardiac end and it is guarded by cardiac sphincter. Lower end called pyloric end and it is guarded by pyloric sphincter.
4. Fundus : a dome shaped upper part lying to the left of cardiac end.
5. Body : the main part of stomach
6. Pyloric antrum : the lower part

STRUCTURE OF STOMACH

Stomach contains of the following four coats :

1. Peritoneal coat (made of serous covering)
2. Muscular coat (made of longitudinal, circular and oblique fibres)
3. Submucous coat (made of areolar tissue)
4. Mucous coat (made of mucous membrane)

Secretions of Stomach :

The mucous membrane of stomach contains glands which secrete gastric juice continuously. The secretion of gastric juice occurs due to :

1. a reflex mechanism through vagus nerve
2. gastrin, a hormone secreted by the action of food stuffs on gastric mucous membrane.
3. psychological effects produced by taste or smell of food. Gastric juice contains pepsin, rennin, hydrochloric acid and intrinsic factor.

SMALL INTESTINE AND ITS FUNCTION OF DIGESTION AND ABSORPTION

Small Intestine is the part of alimentary canal which extends from the pyloric end of the stomach to caecum (the first part of large intestine).

Parts : Small intestine consists of three parts :

1. duodenum
2. jejunum
3. ileum

Duodenum :

It is C - shaped fixed part which is attached to posterior abdominal wall by peritoneum. The head of pancreas lies in the concavity of duodenum. Also the bile duct and pancreatic duct open together at the concave surface. A small eminence at this opening is called ampulla of Vater.

Jejunum :

It is the continuation of duodenum and it is the middle portion of small intestine

Ileum :

It forms the last part of the small intestine

DIGESTION IN SMALL INTESTINE

The acidic chyme from the stomach enters into the duodenum. There it mixes with :

1. the alkaline intestinal juice called "succus entericus"
2. alkaline secretions from liver and pancreas

In the small intestine, digestion is carried out by the following enzymes of intestinal juice.

1. "Enterokinase" which converts trypsinogen
2. "Erepsin" which converts polypeptides into amino acids
3. "Sucrase", maltase and lactase which convert the corresponding disaccharides into monosaccharides.

Absorption in Small Intestine :

The absorption of digested food occurs in small intestine through villi.

Villi :

Villi are minute projections which are present in the inner mucous coat of the intestine. The villi give a velvety appearance to the intestinal mucous membrane. Each villus has:

1. a central lymphatic vessel called lacteal. Fats are absorbed into lacteal and carried to thoracic duct.
2. a network of capillaries surrounding the lacteal. Digested products of carbohydrates and proteins are absorbed into these capillaries. They are carried to liver by portal vein.
3. lymphoid tissue which holds together the lacteals and capillaries.

LARGE INTESTINE AND ITS FUNCTIONS

Large intestine (colon) extends from the end of ileum to rectum. Large intestine consists of the following parts : caecum, appendix, ascending colon, transverse colon and sigmoid colon.

1. Caecum :

It is a short rounded sac which lies in the right iliac fossa. It commences at ileocaecal valve where the ileum joins the caecum.

2. Vermiform appendix :

It springs out from the caecum at about an inch from the ileocaecal junction. It is present in the right iliac fossa. The lumen of appendix communicates with that of caecum. The appendix is composed of the same four coats as intestine but the submucous

coat contains lymphoid tissue.

3. Ascending Colon :

It ascends upwards from caecum and in front of right kidney. It turns to the left below the liver and forms the transverse colon.

4. Transverse Colon :

It is the loop of large intestine which extends between the lower surfaces of liver and spleen. At the lower surface of spleen, it turns downwards to form descending colon.

5. Descending Colon :

It extends from the lower surface of spleen to brim of pelvis. It lies in the left lumbar region.

6. Sigmoid Colon :

It is the continuation of descending colon and it continues below with rectum.

Structure of Large Intestine :

Large intestine has the same four coats (peritoneal, muscular, submucous and mucous) as small intestine. But the only difference is longitudinal muscles are arranged in three bands . The mucous membrane does not have villi.

DIGESTION OF FOOD IN THE ALIMENTARY CANAL

Food contains :

1. carbohydrates 2. proteins 3. fat.

All these constituents of food are digested in the alimentary canal as follows :

1. Carbohydrates :

Ptyalin (salivary amylase) present in saliva converts cooked starches in food into a sugar called maltose. This conversion occurs in the mouth. All sugars are converted to simple monosaccharides like glucose by the action of enzymes in the small intestine. Glucose is absorbed through the capillaries of villi in the small intestine. It is then carried to liver by portal vein where it is stored as glycogen.

2. Proteins :

The digestive enzymes convert proteins into peptones, polypeptides and finally into amino acids. The amino acids are absorbed through villi of small intestine and carried to liver.

3. Fats :

Lipase, an enzyme of pancreas which is poured into small intestine converts fats into fatty acids and glycerol. These two products are absorbed through lacteals of villi.

They are carried to thoracic duct through cisterna chyli. From the thoracic duct they enter into blood through left brachiocephalic vein.

PERITONEUM

Peritoneum is a serous membrane which lines the abdomen and covers the abdominal organs. It consists of the following two layers.

1. Parietal peritoneum which lines the walls of abdominal cavity
2. Visceral peritoneum which covers the abdominal organs. The space between these two layers is called as peritoneal space.

Organs completely covered by peritoneum are stomach, liver and intestines. Organs partly covered by peritoneum are kidney.

Omenta :

The folds of peritoneum connected to the stomach are called omenta. They are divided into :

1. Greater omentum which hangs from the lower border of stomach to the front surface of small intestine.
2. Lesser omentum which extends from the lower border of liver to the lesser curvature of stomach.

Mesentery :

It is the fold of peritoneum which attaches the different parts of small intestine to the posterior abdominal wall. Blood vessels, nerves and lymphatics enter the intestines only through mesentery.

Peritoneal ligaments :

They are folds of peritoneum which connect organs (like liver

and uterus) to the posterior abdominal wall).

Pelvic Peritoneum :

It is the part of the peritoneum present in the pelvic region. The pelvic peritonum is actually the continuation of peritoneum in the abdominal cavity. The arrangement of pelvic peritoneum is different in males and females due to the presence of uterus and fallopian tubes in females.

Arrangement in males :

In males, the peritoneum covers the upper part of rectum. Then it passes over the posterior and upper surface of bladder. Later, it becoems continuous with the peritoneum of anterior abdominal wall.

Arrangemnt in females :

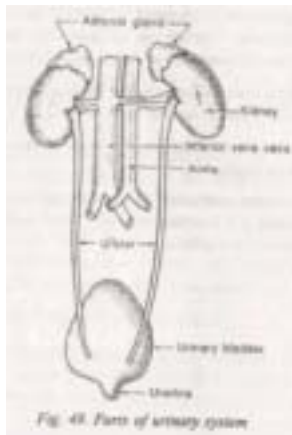
In females the peritoneum covers the rectum as in males. But it covers the anterior and posterior surfaces of uterus before reachng the bladder. The sac of peritonium between the rectum and uterus is called the Pouch of Douglas. In the females, the peritoneum covers the fallopian tubes also. the fallopian tubes open directly into the peritoneal cavity. The mucous membrane of fallopian tubes is continus with peritoneum.

Functions of Peritoneum

1. It forms a complte or partial covering for abdominal organs
2. It forms a smooth lining which enables the abdominal organs to move over each other without friction.
3. The ligaments and mesentries of peritoneum hold the abdominal organs in position.
4. Omentum and mesentry serve as store house for fat
5. The fat of peritoneum prevents infections being carried to abdominal organs.
6. The peritoneum contains some fluid which absorbs shock and prevents it from getting transmitted to abdominal organs.
7. The peritoneum itself can absorb large quantities of fluids.

10. EXCRETORY SYSTEM

The urinary system is the main excretory system of the body. It consists of 1) two kidneys 2) two ureters 3) an urinary bladder 4) an urethra.



KIDNEY:

They are two bean shaped organs lying on the posterior abdominal wall, on each side of the vertebral column.

Functions of the kidneys:

1. Excretion of water and waste products of protein metabolism.
2. Excretion of excess salt.
3. Excretion of harmful substances, drugs and toxins.
4. Regulation of pH of blood.

Positions of the kidneys:

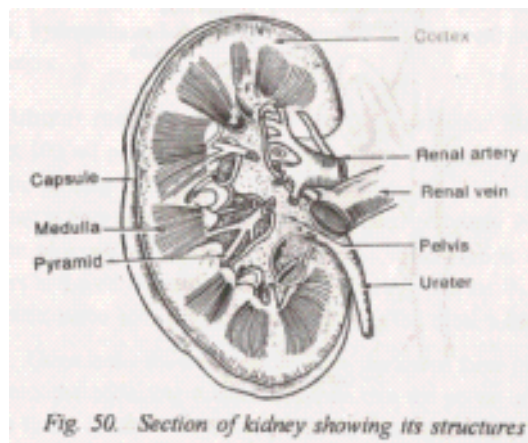
The kidneys extend from the level of last thoracic vertebra to the third lumbar vertebra. The right kidney is smaller than the left kidney. Each kidney measures 11 cm in length 5 cm in width and 3 cm in thickness. Each kidney weighs about 150 grams.

The outer border of kidney is "convex". The inner border is concave and it is called as "hylum". Blood vessels enter and leave the kidney through the hylum. A suprarenal gland is situated at the apex of each kidney.

Structure of kidney:

Kidney is surrounded by an outer fibrous capsule. Below this lies the substance of the kidney which-consists of:

1. An outer cortex which is reddish- brown in colour.
2. Inner medulla which contains "pyramids" of the kidney.



3. An upper expanded end or ureter called "pelvis".

Microscopically the kidneys are made of a number of structural and functional units called "nephrons". There are about one million nephrons in each kidney. A nephron consists of two parts:

1. Malphigian bodies made of Bowman's capsule and glomerulus.
2. Renal tubules.

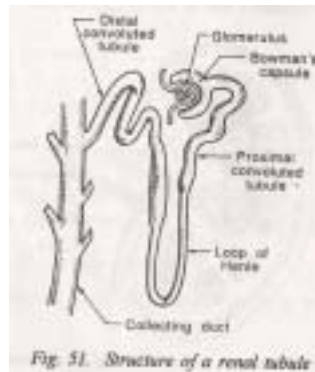
Malphigian bodies:

It is made of 1) an upper expanded end of the renal tubule called "Bowman's capsule" 2) a bunch of capillaries called "glomerulus" which are packed in Bowman's capsule. The malphigian bodies are present in the cortex.

Renal tubules:

They consist of four parts:

1. Proximal convoluted tubule situated in the cortex.
2. Loop of Henle present in the medulla.
3. Distal convoluted tubule present in the cortex.
4. Collecting tubules which pass through the medulla and open into the pelvis of kidney.



Blood supply to kidney:

Kidneys are supplied by renal arteries which are branches of abdominal aorta. Venous blood of kidney is drained by renal veins which open into inferior vena cava.

FORMATION OF URINE:

The formation of urine by kidneys involves three processes:

1. Glomerular filtration
2. Tubular secretion
3. Tubular reabsorption

1. Glomerular filtration:

Filtration of water, salts and other substances occurs in the glomeruli. Glomerular filtrate is the fluid that is formed after filtration. About 100 ml of glomerular filtrate is formed per minute. This filtrate passes into the proximal convoluted tubule.

2. Tubular secretion:

It is an active process which occurs in the convoluted tubules. Abnormal substances or normal substances present in excess in blood are eliminated by this process. Potassium, hydrogen and drugs like penicillin are excreted by tubular secretion.

3. Tubular reabsorption:

The rate of glomerular filtration is about 100 ml per minute. So about 6 litres of glomerular filtrate can be formed in one hour. But the volume of urine eliminated per day is only about 1.5 litres. It is so, because nearly 99 percent of the glomerular filtrate is reabsorbed. Reabsorption of water occurs in the convoluted tubules and collecting tubule. In addition to water, some salts are also

reabsorbed in the renal tubules.

Urine is the fluid that results from the above three processes. It enters the collecting tubules and then into the pelvis of kidney. From there, it enters the urinary bladder through ureter.

URETER:

It is the duct which carries urine from the kidney to bladder. It is a tube like structure measuring about 26 cm in length. It commences from the pelvis of kidney. Later it passes down in the abdominal cavity and opens in the posterior aspect of urinary bladder. Ureter is made of 1) an outer fibrous layer 2) middle muscular layer 3) inner mucous layer.

URINARY BLADDER:

It is a pear shaped muscular sac which acts as a reservoir for urine. It lies in the pelvic cavity behind symphysis pubis. The lowest part of bladder is called as base and the upper part is called "fundus".

Bladder has three openings, two for ureters and one for urethra. The triangular area between these openings is the "trigone of the bladder".

Bladder is made of four layers 1) outer serous coat 2) muscular coat 3) sub-mucous coat 4) mucous lining made of transitional epithelium. The bladder is controlled by pelvic nerves and sympathetic fibres from hypogastric plexus.

URETHRA:

It is a canal through which urine passes from the bladder to the outside. It differs in the males and females. But a sphincter is present in both.

Male urethra :

It is about 20cm in length. It consists of three parts 1) Pelvic part 2) Perineal part 3) Pineal part.

Female urethra:

It is short and measures about 4 cm in length. It starts from the base of bladder at the trigone. It opens externally in front of

vaginal opening

MICTURITION:

It is the act of passing urine. When urine accumulates in the bladder, it produces stretching of its walls. This raises the pressure within the bladder. This occurs when 170 to 230 ml of urine has collected in the bladder. This in turn stimulates the afferent nerves of the bladder. The impulses are carried to higher centres which control micturition.

Micturition occurs due to contraction of muscular coat of the bladder and relaxation of the sphincter. It is also assisted by contraction of abdominal muscles.

Composition of urine:

The volume of urine excreted in man varies from 1 to 2 litres daily. The colour of urine is pale amber odour is aromatic and reaction is slightly acidic (pH 6). Specific gravity varies from 1010 to 1025.

Urine consists of:

- | | |
|------------------------|-------|
| 1. Water | - 96% |
| 2. Urea | - 2% |
| 3. Uric acid and salts | - 2% |

DISEASES OF THE URINARY SYSTEM

- 1. Glomerulo nephritis** - an infection of kidney leading to inflammation of glomeruli.
- 2. Pyelitis** - an inflammation in pelvis of kidney due to infections.
- 3. Polyurea** - secretion of large quantities of urine.
- 4. Anurea** - cessation of urine secretion.
- 5. Renal calculi** - deposition of insoluble substance in urinary tract.
- 6. Cystitis** - inflammation of urinary bladder.

OEDEMA:

It is water logging of the tissues. It occurs as swelling of the body or any part of the body due to retention of fluid. Oedema can occur due to a variety of causes.

Oedema of renal failure:

It occurs as follows: Plasma proteins are excreted in kidney

failure. This produces a decrease in osmotic pressure, of blood. So entry of fluid at the venous side is decreased. This leads to accumulation of fluid in tissue spaces. It results in swelling leading to oedema.

Cardiac oedema:

It occurs in congestive cardiac failure. Because of inefficient contraction of the heart, venous fluid is not effectively mobilised to the heart. So fluid accumulates in tissues producing oedema.

Oedema of lymphatic obstruction:

It occurs mostly after radical mastectomy (removal of breast). In this procedure, the lymph glands which drain the axilla are also removed. So oedema occurs because of obstruction to lymphatic flow.

Oedema also occurs in elephantiasis caused by filariasis. Oedema is due to obstruction of the lymphatics by the parasite.

Oedema of thrombosis:

It is seen in thrombosis of deep veins of legs. It is due to prolonged, confinement to bed due to which flow of blood is sluggish. So clots form which further obstruct blood flow producing oedema.

11. SKIN AND REGULATION OF BODY TEMPERATURE

Skin is the outer covering of body which is in contact with external environment.

Functions of skin

1. Protection of underlying structure from injury.
2. Excretion of salts like sodium chloride and metabolites like urea.

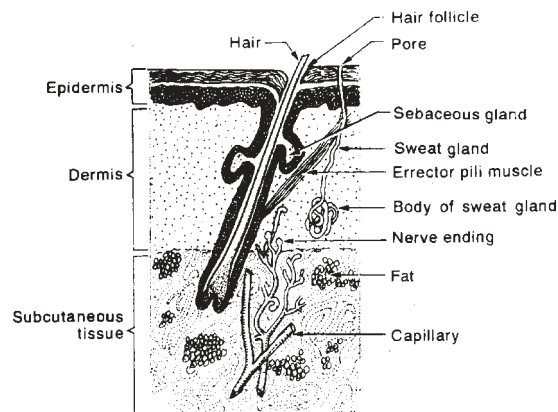


Fig. 75 Structure of skin

3. Provides sensation which gives the awareness of environment
4. Secretion of sweat and sebum.
5. Regulation of body temperature.
6. Synthesis of Vitamin D from ergosterol of skin by the action of ultraviolet rays of sun.

Structure of skin: Skin consists of

1. An outer layer called *epidermis*
2. An inner layer called *dermis*.

Epidermis : It is made of stratified epithelium and contains the following layers:

1. Stratum corneum - Containing scale like cells which are constantly replaced. These cells have a protein called keratin.

2. Stratum Lucidum - A glistening layer.
3. Stratum granulosum - Has spindle shaped cells with granules in the cytoplasm.
4. Stratum germinativum- Contains cuboidal cells. The skin cells multiply in this layer.

Dermis: It is the inner layer which forms true skin. It contains the following structures :

1. Melanophore cells containing melanin pigment and some elastic fibers which maintain texture of skin.
2. Arterial and venous capillaries and sensory nerve endings.
3. Sweat and sebaceous glands.
4. Hair roots and errector pili muscles (contraction of these muscles produce straightening of the hair).

SECRETIONS OF SKIN : The two secretions of skin are sweat and sebum.

Secrtion of sweat : Sweat is secreted by sweat glands which arise from dermis. They are twisted tubular glands and their ducts open in epidermis. Sweat glands are more numerous in the palms of hands and sole of feet. About 500ml of sweat is formed in 24 hours.

Sweat contains mainly water, some salts and trace of other waste products.

Perspiration of sweating can be classified into :

1. *Insensible perspiration* which evaporates quickly and so it is not observed.
2. *Sensible Perspiration* Which occurs during excerssive sweating. So production of sweat is more than evaporation.

The secretion of sweat is controlled by symphothetic by symphathetic nerves.

Secretion of sweat : Sweat is a greasy secretion produced by sebaceous glands. They have a duct which opens into hair follicle. The sebaceous glands are present in the skin of many parts except the palm of hands and sole of feet. Sebum keeps the skin oily and

prevents it from drying.

REGULATION OF BODY TEMPERATURE : Regulation of body temperature is an important performed by the skin. The normal body temperature is 98.4° (37°C), It may be slightly lower in the morning and it may increase in severe muscular exercise. The normal body temperature is maintained by a balance between heat production and heat loss.

Heat production : heat can be produced in the body by the following factors :

1. Increased activity of muscles as in severe exercise.
2. Increased activities of liver and other glandular structures.
3. Increased metabolism like oxidation of food stuffs and combustion of fat.

Heat loss : Loss of heat occurs through the skin by :

1. Conduction to objects in contact like clothing.
2. Convection by which the hot air around the body moves up and it is replaced by cool air.
3. Radiation by which heat is given to the surrounding air.
4. Evaporation of sweat makes the skin cool and leads to heat loss.

Body temperature is controlled by 'Heat regulating centre' present in the hypothalamus.

PHYSIOLOGY OF PAIN : Pain is a protective mechanism which warns the body against disorder and defects in its parts. Pain can be classified into : i) Cutaneous pain ii) Visceral pain iii) deep pain iv) head-ache.

- i) **Cutaneous pain :** It may be produced by : 1) pathological states of skin 2) Injury to skin 3) release of chemical cases,

the painful area may extend beyond the damaged or diseased area.

- ii) Visceral pain :** It may occur due to an altered physiology of an internal organ like kidney, liver etc., Sometimes sensation of pain is displaced from the affected area and felt at adjacent areas and it is called as referred pain e.g. pain arising from liver is felt in the skin of right shoulder.
- iii) Deep pain :** It arises from the receptors of muscles, tendons and joint e.g. powerful contraction of a muscle may occlude blood supply to the muscle and this may cause pain. Like visceral pain, deep, muscle pain can also be referred to the surface of body.
- iv) Head-ache :** Headache may occur due to a variety of conditions like anxiety, tension, pathological changes in intracranial blood vessels or visual defects.

Pathway of pain : The sensation of pain is carried by non-myelinated afferent nerve (which originate from the area of pain) to dorsal horn of gray matter of spinal tract. From here, the sensation is carried to thalamus through spinothalamic tract. From the thalamus, the impulses are carried to subcortical area for crude sensation and then to cerebral cortex.

12. REPRODUCTIVE SYSTEM

MALE REPRODUCTIVE SYSTEM : The organs of male reproductive system can be classified into :

1. External genital organs : Penis containing the urethra.
2. Internal genital organs : Testes
Vas deferans
Semenal vesicles
Prostate glands.

PENIS : It is the copulatory organ and also it contains the terminal part of urthra. The parts os penis are :

1. *Corpora cavernosa* which are two pillars of erectile issue lying side by side under the skin of penis.
2. *Corpora spongiosum* contains the urethra and it lies below corpora cavernosa.
3. *Glans penis* which is the eclarge tip of penis.
4. *Propuce* which is a fold of skin covering the glans penis.

TESTES

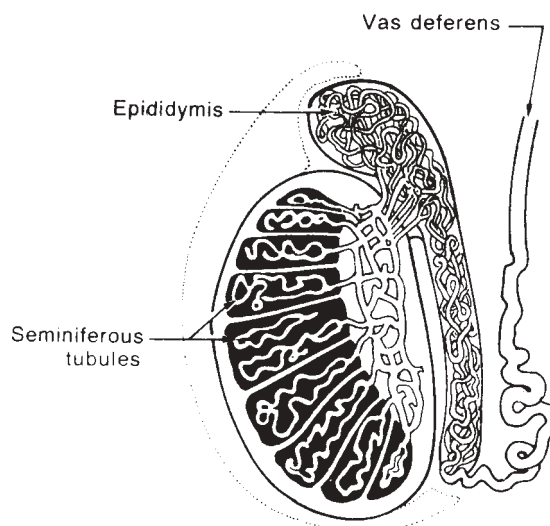


Fig. 89 Internal structure of testis

Position : Testes are the male reproductive organs which produce spermatozoa. The testes are two oval shaped bodies lying one on each side in the "scrotum". The scrotum forms a bag of puch for the two testes. Each testes is enclosed in a sac called *tunica vaginalis* which is derived from peritoneum.

The testes are actually suspended in the scorotum by means of *spermatic cord*.

Structure : Each testis (or Testicle) contains a number of tubules called *seminiferous tubules*. The seminiferous tubules unit at the upper end of these seminiferous the upper end form epididymis. The epididymis forms the commencement of vas deferens (or seminal duct).

In between the seminiferous tubules there are interstitial cells(Ledig cells) which secrete testosterone.

VAS DEFERENS : (Seminal duct): They are two in number one for each testis. The vas deferens commences from the epididymis at the upper end of testis. It travels upwards within the spermatic cord and enters the abdominal cavity through the inguinal canal. From the abdominal cavity, the vas deferens enters the pelvis and joins of the bladder.

SIMINAL VESICLES :

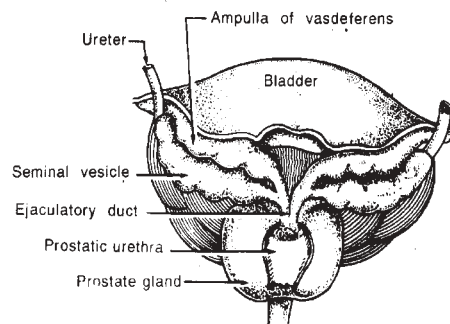


Fig. 90 Position of internal genital organs in males

They are two in number, each one lies at the side of the terminal part of vas deferens.

The seminal vesicle joins with the terminal portion of vas deferens and the *ejaculatory duct*. The ejaculatory duct pierces the prostate gland and opens into the ejaculations.

PROSTATE GLAND : The prostate gland lies below the bladder and it surrounds the first part of urethra. It is pyramidal in shape. Its base is directed above and it is in contact with the inferior surface of bladder. The apex is directed downward. The prostate consists of glands, ducts and involuntary muscles. The prostate secretes a fluid which is conveyed to the urethra through ducts.

Semen: Semen is the compound secretion of testes, prostate and seminal vesicles. Semen acts as a vehical for spermatozoa and also it provides nutrition to the spermatozoa.

Semen is a thick, Whitish fluid which is very viscous in nature. It is slightly alkaline and has a pH of about 7.4. Each ejaculation produces 3ml of semen. Each ml. of semen normally contains about 60 to 100 millions spermatozoa.

SPERMATOOZOA : Spermatozoa are produced by the seminiferous tubules of testes. Each spermatozoan contains a head, body and tail. The spermatozoa are highly motile and there function is to fertilise the ovum in the female genital tract.

FEMALE GENITAL ORGANS : The female genitgal organ can be classified into :

1. Secondary organ : Breast (or mammary glands)
2. External genital organs : Mons veneris
Labia majora
Labia minora

- Clitoris
 Hymen
 3. Internal genital organ : Vegian
 Uterus
 Oraries
 Fallopian tubes

BREAST (Mammary glands) : They are accessory of secondary reproductive organ in the female. They secrete milk. The mammary glands are rudimentary in the males.

Position : The breasts lie on the pectoralis major muscle of both sides. On the sides, they extend between sternum and axilla. From above downwards, they extend between the 2nd and 6th rib.

External features : The breasts are more or less hemispherical in shape. They contain a small prominence in the middle called *nippel*. Areola is a coloured area which suroronds the nipple.

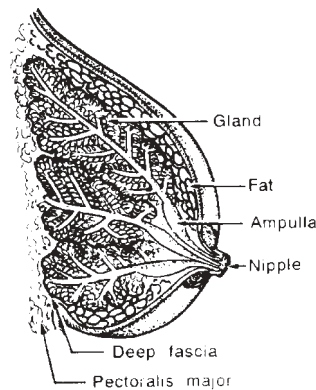


Fig. 91 Internal structure of breast

Internal Structure : The breast consist of a number of lobules which are nade of columnar epithelium. these lobules are surrounded by fat. The lobules give rise to *lactiferous ducts* which pass towards the nipple. These ducts have an enlargement at the end which is

called *ampulla*.

Development : At birth, the breast is poorly developed and it contains only a rudimentary nipple. At puberty, the breast starts developing and the gland tissue increases. This is due to the action of oestrogen and progesterone secreted by the ovaries. The active development commences at the starting of menstrual life when there is deposition of fat and starting of menstrual life when there is deposition of fat and increase in size. After menopause, the ovaries lose their function and the breast also shrinks.

Secretion of milk : During pregnancy, oestrogen and progesterone secreted by the ovary, stimulate the growth of ducts and lobules of breast. Later, these two hormones are secreted by placenta and produce the same effect. After child birth, the secretion of these two hormones decreases. Now, milk secretion is stimulated by prolactin of anterior pituitary. Oxytocin of posterior pituitary is responsible for milk ejection.

EXTERNAL GENITAL ORGANS : These organs are collectively

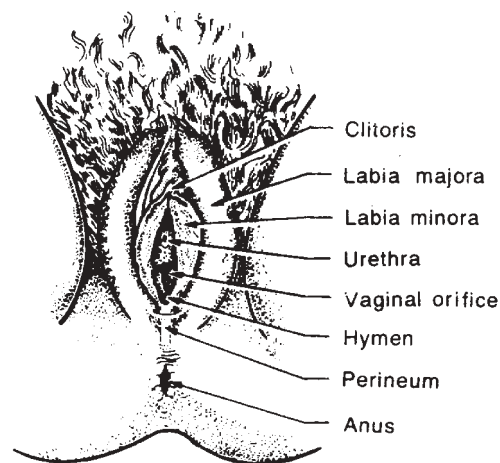


Fig. 92 External genital organs in females

known as vulva and it consists of the following parts :

1. **Mons veneris** (Mons pubis) : It is a pad of fat in the female, lying in front of symphysis pubis. At puberty, this area is covered with hair (public hair).
2. **Labia majora** : They are two round thick folds of skin which form the sides of vulva.
3. **Labia minor** (nymphae) : They are two thin folds of skin which lie in the space enclosed by labia majora. *Vestibule* is a triangular area which is enclosed by labia minora. The vestibule contains the opening of urethra and vagina.
4. **Clitoris** : It is a small erectile body which is situated at the apex of the vestibule. It is a highly sensitive structure and it corresponds with the penis in males.
5. **Hymen** : It is a thin membrane which covers the vaginal orifice of virgin women. It is usually perforated so as to allow menstrual flow.

Internal genital organs

Vagina : It is a canal made of muscular walls. It extends from the vaginal orifice (in vestibule) below to the cervix of uterus above. The vagina is lined by a thin skin which is thrown into a number of folds. A small projection of the vagina above the outer surface of cervix of uterus is called as fornix.

Uterus

Position : Uterus or womb is a hollow muscular organ situated in the

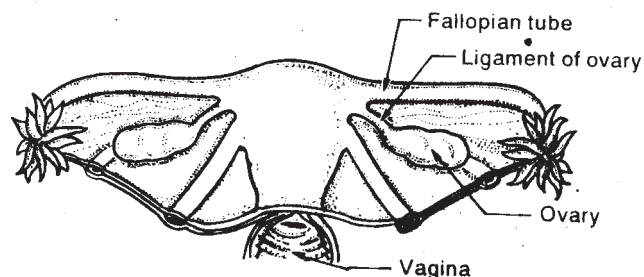


Fig. 93 Diagram of uterus and ovaries

pelvis. It is covered by peritoneum and lies between the bladder in front and rectum behind.

Parts : The uterus can be divided into three parts :

- 1) fundus
- 2) body
- 3) cervix.

Fundus is the upper part which lies above the two openings of fallopian tubes. Body is the part which lies between the fundus and cervix. Cervix is the lower constricted part. The cervix is continuous above with the body of uterus through an orifice called internal os. It is continuous below with the vagina through external os.

Fallopian tubes are attached on either sides of the fundus of uterus.

Ligaments of uterus : The uterus is supported and held in position by means of two ligaments. They are :

i) Two broad ligaments which are folds of peritoneum. They extend between the sides of uterus and the pelvic wall. The layers of broad ligaments contain 1) fallopian tube 2) round ligament 3) blood vessels, nerves and lymphatics.

ii) Two round ligaments which extend from the uterus (below the fallopian tube) to labia majora.

Structure : The walls of the uterus are thick and consist of three layers. They are :

1. Outer peritoneal layer called perimetrium.
2. Middle muscular layer called myometrium.
3. Inner muscular layer called endometrium.

Functions of uterus :

1. Plays an active part in menstruation.
2. Receives the fertilised ovum and retains it during pregnancy.
3. Expels the foetus by contraction of its muscular walls.

Ovaries

Position : The ovaries are two in number. They lie on either side of the uterus. A fold of peritoneum attaches the ovaries to posterior aspect of broad ligament. The ovaries lie below the fallopian tube of each side.

Structure : The ovary contains :

1. A central soft tissue called stroma.
2. An outer surface called germinal epithelium.

The germinal epithelium contains the graffian follicles. The graffian follicles contain the ova. The ova are surrounded by a fluid called liquor folliculi.

Ovulation occurs due to the rupture of the graffian follicles. Corpus luteum is the graffian follicle which has liberated its ovum.

Functions of the ovary :

1. Formation, development and liberation of ova.
2. Secretion of oestrogen (by graffian follicle).
3. Secretion of progesterone (by corpus follicle).

Fallopian Tubes (Uterine tubes) : The fallopian tubes are two in number. They arise one on each side from the upper angles of uterus. They lie in the upper margi of broad ligament of uterus.

Parts : The fallopian tube has 1) an uterine end 2) an ampulia 3) a fumbrial end.

- 1) The uterine end is attached to the walls of uterus. The opening at this end continues with the cavity of uterus.
- 2) The ampulla is a slight enlargement near the fumbrial end.
- 3) The fumbrial end is the terminal portion of fallopian tube.

This end has i) finger like processes called fumbriae ii) an opening which gives access to the peritoneal cavity.

Structure : The fallopian tube consists of

1. Outer pertitoneal layer
2. middle muscular layer
3. inner' mucous layer

Functions : The fallopian tube acts as a passage for ova from the ovary to uterus. Usually, the fertilisation of ovum by spermatozoa occurs in the fallopian tube.

Puberty in females : Puberty is the age at which internal reproductive organs mature. It usually occurs at the age of 10 to 14 years in girls. It is marked by the onset of menstruation (the menarhce). The physical and physiological changes which occur at pubrty are :

1. maturation of ovaries, uterus and uterine tubes.
2. enlargement of vagina and breasts.
3. growth of axillary and public hair.
4. increased growth and widening of pelvis.
5. onset of menstruation and ovulation.
6. increased deposition of fat in subcutaneous tissue.
7. mental and emotional maturity.

Ovulation : Maturation of the graffian follicle and liberation of ovum is termed as ovulation. The ovary contains graffian follicles. These follicles are about 40,000 in number. They are formed even during foetal

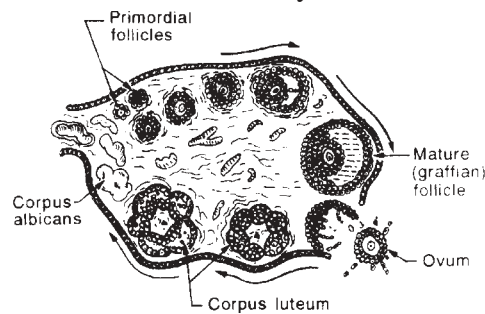


Fig. 94 Ovary showing primordial follicle, graffian follicle and corpus albicans

Ovulation occurs due to the rupture of the graffian follicles.

life. The rest get degenerated. But all the follicles are lost at menopause.

Ovary showing primordial follicle, graffian follicle and corpus albicans.

Ovulation occurs due to the reapture of the graffian follicles. This is stimulated by luteinising hormone (LH) of anterior pituitary. After discharging the ovum, the graffian follicle forms the corpus leteum. Estrogen is produced by the corpus luteum. If pregnancy takes place, the corpus luteum persists upto 5th or 6th month of pregnancy. If pregnancy does not take place, the corpus luteum and gets atrophied and gets atrophied and forms Corpus albicans.

Ovulation occurs at about the 14th day of menstrual cycle. The ovum is discharged into the pertioneal cavity. It is carried to the fallopian tube by the action of fimbriae. The ovum gets fertilised in the fallopian tube and later gets embedded in the uterine wall. If the ovum is not fertilised, it is discharged through menstrual flow.

Menstruation : Menstruation starts at puberty. It stops temporarily during pregnancy but permanently at menopause. It occurs almost every 28 days. Menstruation involves periodic discharged of blood from uterine cavity. During menstrual cycle, the endometrium undergoes

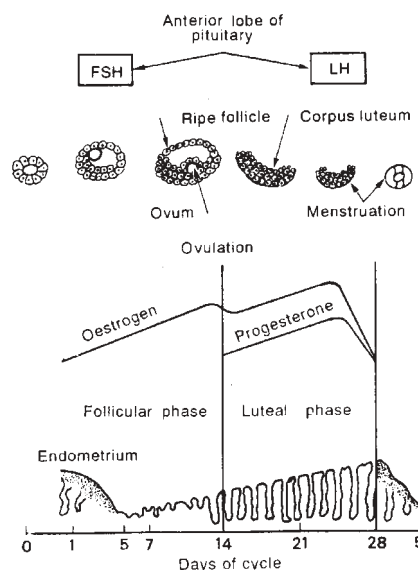


Fig. 95 Changes in the endometrium during menstrual cycle

cyclic changes and is prepared to receive the fertilised ovum. These endometrial changes are also associated with changes in the ovary. Menstrual cycle can

Changes in the endometrium during menstrual cycle be divided into the following phases based on changes occurring in the uterus :

1. Destructive phase (Menstrual phase) : It is the phase lasting for the first five days of the cycle during which menstrual bleeding occurs.

2. Follicular phase (Proliferative phase) : It extends for the next 9 days. During this time, repair of the endometrium occurs. At this stage, the graffian follicle of ovary matures (for this FSH of anterior pituitary is necessary) and ova develop inside. The graffian follicle now secretes oestrogen. Around the 14th day of the menstrual cycle, the graffian follicle ruptures and releases the ova. The graffian follicle now becomes corpus luteum.

3. Luteal phase (Secretory phase) : It is the phase lasting for the next 14 days. During this phase, the endometrium becomes thick and vascular so as to receive the fertilised ovum. Now the corpus luteum secretes progesterone (For this LH of anterior pituitary is necessary). If conception occurs by implantation of the fertilised ovum, the secretion of progesterone continues throughout pregnancy. Otherwise the corpus

Uterus begins to degenerate and does not produce progesterone. Later, the capillaries of endometrium burst and menstruation occurs (The first day of menstrual flow is designated as Day 1 of menstrual cycle).

Menopause (Climacteric) : It is the cessation of menstruation which occurs in a woman's life at about 45 years of age. It is caused by changes in the concentration of sex hormones. The ovaries become less responsive to FSH and LH. So ovulation and menstrual cycle become irregular and stop ultimately. Menopause is accompanied by certain changes like 1. flushing and sweating 2. shrinkage of breast 3. atrophy

Physical changes during pregnancy

Gynecology :

Labour (child birth, Parturation)

Full term labour takes place up to 40 weeks of pregnancy, but normal limits are within 2 weeks either side of this estimated delivery date. (EDD).

Signs of labour

1. Cervix is dilated more than 2cm.
2. Contractions are strong, regular and frequent.
3. During early cervical dilatation, Mucus substance called "the Show" is discharged
4. Natural rupture of of amniotic membranes termed "waters breaking" usually occurs in labour.

Various stages of labour:

There are 3 stages of labour

1. First stage - Cervical dilatation:

- This takes 12 hours in primary gravida 8 , 7 1/2 hours in secondary gravida.

- Contractions increase variability, until cervix is fully dilated

- Each contraction produces a wave of sensation, starting with

a feeling of tightening in the abdomen and reaching the peak of intensity before dying away.

- Pain also felt in the lumbar, Pubic & often the thighs.

Second stage:

The birth primigravida

- Thus takes of 1 hour in 8-15 minutes in multigravida.

- Pushing and straining of diaphragm and abdominal muscle reflexly strain uterus to expel the baby through the curved birth canal.

- Expulsion effort delivers anterior shoulder first from under pubic and then posterior shoulder trunk & legs. The baby is born.

3. Third Stage:

The cord divided near the baby abdomen and within 5 minutes of so of birth the placenta has separated from the uterus. Placenta is expelled with the cord and membrane. This completes the labour.

Clinical Management:

1. **Episiotomy** : A small incision in the perineum will make a much larger space for baby to deliver.
2. **Forceps extraction**: The blades of forceps on the sides of the baby's head & gentle smooth movements are used with uterine contractions to lift the baby out.
3. **Cesarean section**: A transverse incision is made through the skin and muscles of the lower abdomen known as "Bikini Incision" so that baby and placenta may be removed.

Clinical Management for Pain During Labour

1. **Analgesics** : Pethidine is a muscle relaxant and also induces drowsiness. It also helps in controlling pain during labour.

2. **Epidural analgesia:** Anadesthetic agent intraduced into dural space between the durameter & the perisosteum. It also helps in controlling pain.

Physiotherapy Managenment During Labour:

Application of TNS, in the lower abdominal ragion helps in controlling the pain.

2. Physiological changes during Pregnancy:

Different Physiolgical changes are:

1. Uterus grows from a weight of 50gms. to 950gms. at term.
2. Endometrium Thickness as blood supply increases.
3. The cervik and vagina are more vasucular and sgter with increased secretion of mucus.
4. Abdominal muscle fibers lengthen and as the liner alba sperates (diastheses).
5. Skin pigmentation causes the nipples and ageola to darken and a fine brown line.
6. Tdadrnone called ralanin is raleased into body, it causes hypermobility os joints.
7. There is 50% increase in bliid plasma-volume by 34th week.
8. White cell count increases to give protection agaent infection.
9. Urinary tract infections some times occur due to the bladder and uternus encouraging urinary stasis.
10. Thyriod, Suprarenal and pitutary endocrine gladns enlarge to improve their metabolic function.
11. Posture and gait changes as the weight increases in the abdomen and pelure joints relax.
12. Center of gravity shifts forwards resulting in sttain on the lumbar spine as abdominal muscles lengthen.

13. FAMILY PLANNING AND TYPES OF CONTRACEPTIVES

Population problem : Increase in population is an important problem of India. India is the second populated country in the world next to China. India's population is nearly 700 millions. If growth rate is not checked, the population is expected to reach 1000 millions by 2000 A.D. The increase in population is due to advances in medical sciences, nutrition and control of various diseases. Increase in birth rate is due to lack of family planning.

Family planning : Family planning is a family health and welfare programme with the following objectives. 1) To limit child birth 2) to have proper interval between two successive children 3) health care of mother and child.

Contraceptive methods : The methods by which pregnancy can be prevented are classified as follows :

1. Temporary methods
 1. Natural : Rhythm method
Cervical mucus method
Coitus interruptus
Abstinence
 2. Chemical : Foam tablets
Jellies and pastes
 3. Mechanical : Condom
Diaphragm
Intra uterine contraceptive devices (UCD)
 4. Hormonal : Oral contraceptives
 5. Pregnancy - termination : Menstrual regulation
Abortion.
- ii. Permanent methods (Sterilisation)
 1. Males : Vasectomy
 2. Females : Laprascopy

Natural Methods

Rhythm method (Safe period method); A week before and week after menses is considered to be a safe period which can avoid conception. During these days, ovulation does not occur and so pregnancy can be prevented. A few disadvantages of this method are : 1) In case of irregular menstrual cycle, prediction of safe period is difficult 2) Failure

can occur to the extent of 20%

Cervical mucus method : At the time of ovulation, the cervical mucus becomes thin, clear and watery. Days between the 3rd and 7th day of mucus secretion is the period of conception. Coitus can be avoided during these days to prevent pregnancy.

Coitus Interruptus : Withdrawal of the penis before ejaculation is called coitus interruptus. This method is difficult to practice. Also it is not reliable method.

Abstinence : Keeping away from sexual contact is the best method which can prevent pregnancy. But this method is impractical.

Chemical Methods

Foam tablets : These tablets generate foam when moistened and introduced into the vagina. The foam interferes with the free movement of sperm. Also the tablets contain some chemical substances which destroy the sperm.

Advantages : These tablets are cheap and easy to use.

Disadvantages : Irritation or burning sensation in the vagina.

Jellies, creams and pastes : These substances are applied into the vagina by a special applicator, They melt and spread into the vagina producing a spermicidal action. Again these substances should not be used in case of irritation.

Mechanical Methods

Condom : Condoms are made of latex and can be rolled over the penis before sexual intercourse. The condom collects the semen and therefore prevents the entry of sperm into the vagina. Use of condom is a very safe, easy and cheap method. Also it can provide safety against sexually transmitted diseases. The only disadvantage is interference with local sex sensation.

Diaphragm : It is a rubber dome with a flexible rim made of metal or spring. The diaphragm is fitted into the vagina before sexual intercourse. It should remain in place at least 5 hours after intercourse. The diaphragm prevents the entry of sperm into the vagina. It is relatively a safe method

but a doctor or nurse is required to fit the diaphragm.

Intra Uterine contraceptive devices (IUCD)

The intra uterine contraceptive devices are inserted into the uterine cavity. They do not prevent the fertilisation of ovum. But the fertilised ovum is prevented from implantation in the uterus. The two devices commonly used are : 1) Lippes loop 2) Copper - T.

Lippes loop : It is a double - S shaped device made of polyethylene. It has attached threads which project into the vagina. The threads can be easily felt which assures that the loop is in place. The advantages of Lippes loop are :

- 1) easy insertion
- 2) inexpensive
- 3) reversible
- 4) prolonged safety.

Copper - T : Metallic copper has strong antifertility effect. Copper - T when introduced into the uterine cavity dissolves slowly and prevents conception.

Oral Contraceptives

Oral contraceptives commonly called as 'pill' prevent conception by preventing ovulation. The following is the principle behind the use of oral contraceptives. During pregnancy there is a high level of oestrogen and progesterone which are ovarian hormones. These prevent ovulation. So ovulation and therefore conception can be prevented by administering these hormones. The oral contraceptives contain oestrogen and progesterone in the form of tablets. The tablets should be taken for 21 days starting from the 5th day of the menstrual cycle. Advantages of oral contraceptives are : easy administration, reversibility and less failure (0.7%)

Pregnancy - Termination

These methods are used after conception has occurred. These methods include menstrual regulation and abortion.

Menstrual regulation : It involves aspiration of uterine contents within 6 days of a missed period.

Abortion : It is termination of pregnancy before the 28th week of gestation. The first 10 weeks is the safest period for inducing abortion. Abortion can be done by two techniques : 1. Dilatation and curettage (D & C) 2. Vacuum aspiration. The disadvantages of abortion are bleeding, infection and perforation of uterus.

Permanent methods (Sterilisation)

Sterilisation is the method by which a male or female is rendered permanently infertile. The procedure of sterilisation in male is called vasectomy and that in female is called tubectomy.

Vasectomy : It is the sterilisation procedure in males. In this method, a piece of vas deferens is cut and clamped. It is usually done through scrotal route.

Advantages :

1. It is a simple surgical procedure.
2. No hospitalisation is required
3. Most effective and successful method.

Disadvantages : Occasional infections and sperm granuloma.

Tubectomy : It is a sterilisation procedure in the females. In this method, the fallopian tubes of both sides are cut and clamped. This prevents the transport of ovum. The best time for tubectomy is after delivery. At this time, the fallopian tubes are easily approachable. Also an extended stay in the hospital can be avoided when tubectomy is done at this time.

Laparoscopy : It is the recent method of sterilisation in females. By this method, the fallopian tubes are sealed by passing a beam of light from a device. It is a simple and effective method and the patient can be discharged on the same day.

ROLE OF PHARMACIST IN FAMILY PLANNING

Pharmacists work in various capacities throughout the country in most of the villages and towns. In most cases, pharmacists serve as a link between the public and the doctors. So it is likely that pharmacists come

across a number of people with their own beliefs about family planning. The illiterate or less educated people are not aware of the benefits and also the ease of family planning. Most of them have psychic fear that sterilisation is painful, dangerous and harmful to health. The pharmacist has a vital role to play in dispelling such fears.

Pharmacists can promote family planning by :

1. Displaying family planning posters in hospitals and drug stores.
2. Advising people about the importance of family planning, spacing of children etc.,
3. By distributing pamphlets about family planning.
4. Explaining about oral contraceptives and family planning techniques.
5. Guiding people to hospitals and family planning centres for vasectomy or tubercctomy.

Thus pharmacists can provide information, advice and motivation for family planning.

14. METABOLISM OF FAT, CARBOHYDRATES PROTEINS

METABOLISM:

It is defined as biochemical changes which occur in the body in order to maintain its vital functions. Metabolism is classified into

- 1) Anabolism
- 2) Catabolism

Anabolism:

It is a constructive process, it leads to building up of fresh tissues from nutritive materials of food.

Catabolism:

It is a destructive process. It leads to break down of worn out tissues and hair removal for health. Anabolism and catabolism should be maintained at a balance. Health is affected when this balance is upset.

ENERGY OF THE BODY AND ITS SOURCE:

The body requires energy for maintaining its vital functions. In the body energy is derived from food. The following are the sources of energy present in food.

1. Carbohydrates and fats are sources of energy for work and heat.
2. Proteins are sources of energy for growth and repair
3. Vitamins and salts are sources of energy for vital functions.

Calorie:

Energy requirements of the body and the energy value of food is expressed in terms of heat. The unit for measurement of heat is calorie.

Calorie is defined as the amount of heat required to raise the temperature of 1 litre of water by 10C at 150C. The symbol for calorie is C the calorie value of various types of food is as follows:

4C for 1 gram of carbohydrate and complete burning. Raises the temperature of 1 litre of water by Lic.

4c for 1 gm of proteins.

9c for 1 gm of fat

BASAL METABOLISM :

It is defined as the minimum amount of energy required by the body during a period of complete rest. Even during rest, some amount of energy is required to maintain vital functions like eating of heart digestive functions etc. the energy of basal metabolism is 25 Cper kg of body weight in 24 hours. So an average individual weighing 60 kg will require 1500 C for basal metabolism.

In addition to this, another 1500 C is required for performing the daily activities so an individual doing normal work requires about 3000 C per day.

The metabolic rate is minimum at rest. It may be increased by factors like.

1. Increase in body temperature as in fever
2. Decrease in body temperature as in cold climate.
3. Increased muscular work
4. Increased secretion of thyroid hormone.

CARBOHYDRATE METABOLISM

Carbohydrates are present in food, vegetarian food contains more carbohydrates than non-vegetarian food carbohydrates are classified into:

1. Polysaccharides - eg: Starch, Cellulose and glycogen

2. Disaccharides eg : Maltose, Lactose
3. Monosaccharides eg: Glucose and fructose

Metabolism of carbohydrate occur in the following steps or stages:

1. Conversion of polysaccharides into disaccharides
Starch converted into maltose by
 - a) Ptyalin of Saliva
 - b) Amylase of pancreatic juice.
2. Conversion of Disaccharides into Monosaccharides
 1. Maltose is converted into glucose by maltose of intestinal juice.
 2. Sucrose (cane sugar) is converted into glucose by invertase of intestinal juice.
 3. Absorption of Glucose:

This occurs in the stomach and through villi of small intestine. Glucose is utilized immediate they or carried to liver.

4. **Storage of liver:**

In the liver, glucose is converted into glycogen and stored for later use

METABOLISM OF PROTEINS

Proteins are nitrogenous substances which are required for the growth and repair of the body tissues. Proteins are classified as

1 Animal proteins:

Which are present in meat, milk, fish, eggs etc. non - vegetarian foods contain more protein.

2. Vegetable proteins:

Which are present in wheat, beans, peas and some leguminous

plants (vegetarian foods). Metabolism of proteins involve the following stages:

1. Conversion of proteins into amino acids:

The enzyme pepsin of stomach converts proteins into peptones. Trypsin of pancreatic juice and erepsin of intestinal juice convert peptones into amino acids.

2. Absorption of aminoacids:

This occurs through villi of small intestine. The absorbed amino acid are carried to liver.

METABOLISM OF FATS

Fats may be classified into two types

1) Animal fats:

Which are present in meat, egg,, butter etc.

2) Vegetable fats:

Which are present in the oils, the metabolism of fats occurs in following stages.

1.Hydrolysis of fats

This occurs in the intestine, intestinal lipase and pancreatic juice lipase converts fats into fatty acids and glycerol

2.Absorption of fats:

Fatty acids and glycerol are absorbed through lacteals of villi present in small intestine. They enter into blood stream through systema clyci and thoraci duct. They are stored in fat stores of body.

Reconversion:

When demand occurs, these fats taken to liver and reconverted into fatty acids and glycerol. These products are later utilized in tissues.

15. ENDOCRINE SYSTEM

INTRODUCTION :

The endocrine system consists of ductless glands which secrete hormones. The hormones are directly poured into circulation without the help of a duct.

HORMONE :

It is defined as the secretion of an endocrine gland which is transported to a site distant from its origin where it produces its action.

The following are the endocrine glands present in the body

1. Pituitary gland
2. Thyroid gland
3. Parathyroid gland
4. Adrenal glands
5. Pancreas
6. Sex glands (gonads)
7. Thymus
8. Pineal gland

PITUITARY GLAND

Pituitary gland is an endocrine gland which is situated at the base of the brain in a hollow called sella turcica of sphenoid bone. It consists of two main lobes they are

1. Anterior lobe
2. Posterior lobe

These two lobes are connected by pars intermedia (which is small intermediate lobe)

ANTERIOR LOBE OR ANTERIOR PITUITARY

The anterior lobe of pituitary contains three types of

cells namely chromophobe, eosinophil, "basophil".

HARMONES OF ANTERIOR PITUITARY

The anterior lobe of pituitary secretes the following hormones

1. Growth hormone (GH)
2. Thyrotrophic hormone (TSH)
3. Adrenocorticotrophic hormone (ACTH)
4. Follicle-stimulating hormone (FSH)
5. Luteinizing hormone (LH)
6. Leuteotrophic hormone (LTH)

1. GROWTH HORMONE (GH) :

It is necessary for the normal growth and development of the body.

2. THYROTROPHIC HORMONE (TSH)

It regulates the synthesis of thyroid hormone in the thyroid gland.

3. ADRENO CORTICO TROPHIC HORMONE (ACTH)

Stimulates the adrenal cortex to synthesize its hormones

4. FOLLICLE - STIMULATING HORMONE (FSH)

Stimulates a) ovary in females to synthesize oestrogen b) Testes in males to produce the Spermatozoa.

5. LUTEINIZING HORMONE (LH)

Stimulates a) ovary in females to produce the progesterone b) Testes in males to produce the testosterone.

6. LEUTEOTROIC HORMONE (LTH)

Stimulates milk production in females during pregnancy.

DISORDERS OF ANTERIOR PITUITARY

1. Hyper pituitarism:

It may occur in the form of

- 1) Gigantism, caused by the over production of growth hormone in children.
- 2) Acromegaly : Caused by the over production of growth hormone in adults.
- 2) Hypopituitarism :
It may occur in the form of dwarfism which is due to decreased of growth hormone.

POSTERIOR LOBE OR POSTERIOR PITUITARY

The posterior lobe of pituitary secretes two hormones. They are oxytocin and vasopressin.

OXYTOCIN:

It has got two functions

- a) Contractions of uterus during labour (delivery) and to bring about parturition (i.e. birth of baby).
- b) Ejection of milk from the breast .
vasopressin (Anti diuretic hormone ADH)

The functions are :

- i) Decreasing urine output by increasing tubular reabsorption in the kidney.
- ii) Increasing blood pressure by constricting capillaries and Arterioles

THYROID GLAND

The thyroid gland is situated in the lower part of neck on the thyroid cartilage the thyroid gland contains two lobes one on each side of the trachea. These two lobes are connected by an isthmus which lies in front of the trachea.

STRUCTURE

The thyroid gland is divided by means of connective

tissue into a number of lobules each lobule contains a number of spherical cells called follicles. Each follicle is lined by a single layer of cuboidal epithelial cells. The follicles contain a jelly like substance called colloid. The colloid stores the thyroid hormones and releases when needed.

SECRETION OF THYROID HORMONE

The thyroid gland synthesis and secretes two hormones. Thyroxine and triiodothyronine. The synthesis of these hormones occurs in the following four stages.

1. Iodine is removed from plasma and concentrated in the thyroid gland.
2. Iodine is oxidized to iodine.
3. Iodine combines with the amino acid tyrosine and forms
 - i) Monoiodotyrosine (MIT)
 - ii) Diiodotyrosine (DIT)
4. Two molecules of DIT combine to form thyroxine (tetraiodothyronine)
one molecule each of DIT and MIT units to form triiodothyronine.

REGULATION OF SECRETION

The secretion of thyroid hormones is controlled by thyroid stimulating hormones (TSH) of anterior pituitary.

FUNCTIONS OF THYROID HORMONE

The thyroid hormone influence growth and metabolism. The major functions are

1. Increase in oxygen consumption and heat production in tissues.
2. Increase in basal metabolic rate (BMR)
3. Increase in the absorption and utilization of glucose.
4. Anabolic effects like growth promotion and protein synthesis.

5. Increase in the rate of Cholesterol synthesis in livers.
6. Myelination of central nervous system.
7. Storage of iodine

DISORDERS OF THYROID FUNCTION :

Hypothyroidism:

1. Cretinism : Occurs due to intrauterine thyroid deficiency. It produces mental retardation.
2. Myxoedema - Which is due to thyroid deficiency occurring after birth. It produces retardation of physical growth
3. Endemic Goitre : Which occurs due to deficiency of iodine in food. It produces enlargement of the thyroid gland.

HYPERTHYROIDISM

Graves disease which is due to excessive production of TSH. It produces protrusion of eyeballs, rapid pulse and nervousness.

PARATHYROID GLAND

The parathyroid glands are four in number. They are embedded on the posterior surface of the thyroid gland, two lying on each side.

STRUCTURE

The parathyroid glands are composed of masses of epithelial cells. The cells are of two types.

- 1) Chief cells
- 2) Oxyphil cells

The chief cells secrete the parathyroid hormone (PTH) or parathormone.

FUNCTIONS OF PARATHYROID HORMONE

PTH increases calcium level of plasma and extra cellular

fluid. This effect is produced by the following mechanisms.

1. Mobilization of calcium of bone into the extra cellular fluid
2. Increased reabsorption of calcium in the renal tubule.
3. Increased absorption of calcium in the gastro intestinal tract.

REGULATIONS OF SECRETION

The secretion of PTH is not under neuronal hormonal control. A decreasing calcium level of plasma increases the secretion of PTH and vice versa.

DISORDER OF PARA THYROID FUNCTION

Hyperparathyroidism produces osteitis fibrosa.

1. It is characterized by decalcification of bone leading to loss of strength and fibrous appearance.
2. Hypoparathyroidism:
Produces hypocalcemia which leads to tetany.

ADRENAL OR SUPRARENAL GLANDS

The adrenal glands are two in number, one gland each is situated on the top of each kidney.

STRUCTURE

The adrenal gland can be divided into two parts which are different in structure and function.

1. An inner medulla
2. An outer cortex
The cortex has three distinct layers of cells they are .
 1. "Zona glomerulosa" - an outer layer
 2. "Zona fasciculata" - an middle layer
 3. "Zona reticularis" - an inner layer

ADRENAL CORTEX

The Adrenal cortex secretes three groups of hormones are

secreted by three different layers of cortex as follows:

1. Zona glomerulosa secretes mineral corticoids
2. Zona fasciculata secretes glucocorticoids
3. Zona reticularis secretes sex steroids

REGULATION OF ADRENOCORTICAL SECRETION

The secretion of various hormones in the adrenal cortex is controlled by adrenocorticotrophic hormone (i.e. ACTH of anterior pituitary)

DISORDERS OF ADRENOCORTICAL FUNCTION

1. Hypofunction of adrenal cortex produces Addison's disease. It is characterized by loss of weight, hypotension, pigmentation of the skin etc.
2. Hyperfunction produces Cushing's syndrome (moon face) characterized by deposition of fat on face and neck, diabetes and hypertension.

FUNCTIONS OF ADRENALINE AND NOR ADRENALINE

1. Vasoconstriction and rise in blood pressure
2. contraction of splenic capsule and release of RBC's.
3. Dilatation of the pupil
4. Contraction of nictitating membrane in animals
5. Relaxation of the intestine.
6. Erection of the hair due to contraction of erector pili muscles of hair follicles.

PANCREAS

The pancreas lies on the posterior abdominal wall in front of abdominal aorta and lumbar vertebrae. It extends between the C-shaped curvature of duodenum and the spleen. The pancreas contains a head, body and tail.

STRUCTURE

The bulk of pancreas containing exocrine cells called acini, acini secrete the pancreatic juice which is digestive in function. Between the acini, there are some endocrine cells called islets of Langerhans.

ISELETS OF LANGERHANS

The islets are present more in the tail portion of pancreas. The islets constitute to the extent of 1 percent of the net weight of pancreas. There are 1 to 2 million islets in pancreas. The islets contain two type of cells.

1. Alpha cells secrete glucagon
2. Beta cells secrete insulin

GLUCAGON

It is a hormone secreted by the alpha cells of islets of Langerhans its functions are:

1. Increase in blood sugar level by mobilizing glycogen from the liver.
2. Mobilising of stored fat
3. Release of insulin from pancreas

INSULIN

It is a hormone secreted by beta cells of islets of Langerhans. The important action of insulin is to decrease the level of glucose in the blood. This effect is produced as follows:

1. Increase glycogen synthesis but preventing glycogen breakdown in the liver.
2. By preventing fresh synthesis of glucose.
3. Stimulating the uptake utilization of glucose in the skeletal muscle.

4. Promoting the conversion of glucose into fat in the adipose tissue.

DISORDERS

Decrease in the synthesis of insulin process diabetes mellitus.

SEX GLANDS

The sex glands are

1. Ovaries in the females which secrete oestrogen and progesterone
2. Testes in the male which secrete androgens

Oestrogen :

It is the female sex hormone secreted by the ovaries its functions are

1. Regulations of menstrual cycle
2. Development of Secondary sex characters

The secretion of Oestrogen is controlled by follicle stimulating hormone (FSH) of anterior pituitary.

PROGESTERONE

It is also a female sex hormone secreted by the ovary its functions are:

1. Maturation and development of uterus and breast.
2. preparation of the uterus to receive the fertilized ovum.

ANDROGENS

They are male sex hormones secreted by "interstitial cells" of the testes. The most important androgen is testosterone. The important functions of androgens are

1. Stimulation of spermatogenesis
2. Growth of penis, scrotum, and prostate
3. Development of secondary sex characters.

The secretion of Androgens is controlled by luteinising hormone (LH) of anterior pituitary.

THYMUS

It is a gland present in the upper chest cavity on the trachea. It lies behind the sternum, but in front of heart and arch of Aorta. It consists of two lobes. Each lobe consists of a number of lobules. The thymus is bigger in size at birth. It grows in size until puberty. Later it gradually decreases in size.

FUNCTIONS

The thymus contains lymphoid tissue. It takes part in the production of lymphocytes. A hormonal secretion of thymus plays some role in sexual development.

